IVUS and CO_2 angiogram for aortic disease: strategy to minimize the use of contrast

Igor Rafael Sincos, MD, PhD, MBA
Clínica Endovascular São Paulo
Diretor Executivo ScIENCE / Curso Veins
Hospital Albert Einstein / São Camilo / Samaritano
igorsincos@einstein.br / drigor@endovascularsp.com.br

Journal of the American College of Cardiology
Vol. 51, No. 15, 2008
ISSN 0735-1097/08/$34.00
doi:10.1016/j.jacc.2007.12.035

Published by Elsevier Inc.

STATE-OF-THE-ART PAPER

Contrast-Induced Acute Kidney Injury

Peter A. McCullough, MD, MPH, FACC, FACP, FAHA, FCCP
Royal Oak, Michigan

- **Contrast-induced acute kidney injury** (AKI) is an important complication after the use of iodinated **contrast media**
- **Significant Economic impact**: with more procedures and longer hospital stay
- the most important risk is **Compromised renal function**

Journal of the American College of Cardiology
Vol. 51, No. 15, 2008
ISSN 0735-1097/08/$34.00
doi:10.1016/j.jacc.2007.12.035
Published by Elsevier Inc.

STATE-OF-THE-ART PAPER

Contrast-Induced Acute Kidney Injury

Peter A. McCullough, MD, MPH, FACC, FACP, FAHA, FCCP
Royal Oak, Michigan

- **Contrast-induced AKI is defined as:**
  - an increase in serum creatinine within **the first 24 h** after contrast exposure
  - and **peaking up to 5** days afterwards

- The most commonly used definition in clinical trials is:
  - a **rise in SCr of 0.5 mg/dl** or a **25% increase** from the baseline value, assessed at 48 h after the procedure.

American College of Cardiology Risco de IRA

- eGFR < 60 ml/min/1.73 m2
- DM
- Intraarterial injection
- Contrast with high osmolality
- Emergency and hypotension
- Volume of contrast >100 ml

Epidemiology

- In a large retrospective study of over 16,000 hospitalized patients, a total of 183 cases of contrast-induced AKI
- **Mortality raised from 7 to 34%** in matched control
- After adjusting for comorbid disease, patients with AKI had a **5.5-fold increased risk of death**

Levy EM, Viscoli CM, Horwitz RI. The effect of acute renal failure on mortality. A cohort analysis. JAMA 1996;275:1489 –94.

Journal of the American College of Cardiology
Vol. 51, No. 15, 2008
ISSN 0735-1097/08/$34.00
doi:10.1016/j.jacc.2007.12.035

Published by Elsevier Inc.

STATE-OF-THE-ART PAPER

Contrast-Induced Acute Kidney Injury

Peter A. McCullough, MD, MPH, FACC, FACP, FAHA, FCCP
Royal Oak, Michigan

- After Internvetional prodcedures: Contrast-induced AKI is associated **worst adverse outcomes**
- 16% rate of death or MI at 1 year after PCI;
- rising to 26.3% if CK-MB levels were also elevated

Journal of the American College of Cardiology
Vol. 51, No. 15, 2008
ISSN 0735-1097/08/$34.00
doi:10.1016/j.jacc.2007.12.035
Published by Elsevier Inc.

STATE-OF-THE-ART PAPER

Contrast-Induced Acute Kidney Injury

Peter A. McCullough, MD, MPH, FACC, FACP, FAHA, FCCP
Royal Oak, Michigan

- American College of Cardiology/American Heart Association recomend the use of IOCM as a class I, Level A of Evidence:

- **Low or Isosmolal contrast**

Journal of the American College of Cardiology
Vol. 51, No. 15, 2008
ISSN 0735-1097/08/$34.00
doi:10.1016/j.jacc.2007.12.035
Published by Elsevier Inc.

STATE-OF-THE-ART PAPER

Contrast-Induced Acute Kidney Injury

Peter A. McCullough, MD, MPH, FACC, FACP, FAHA, FCCP
Royal Oak, Michigan

- **Volume of contrast** is a important **risk factor**

- As a **general rule**, the volume should **not exceed twice** the baseline level of **eGFR** in milliliters

Strategies for Reducing Risk

- **Avoiding nephrotoxic drugs:**
  - nonsteroidal anti-inflammatory drugs,
  - calcineurin inhibitors,
  - high-dose loop diuretics,
  - aminoglycosides, and other

- **Volume expansion** = **1-1,5 ml/kg/h of intravenous fluid**
- for **3 to 12 h before and 6 to 12 h** after contrast exposure

- **Dialysis and hemofiltration** should be considered only in the **very highest-risk** patient after nephrology consultation

Pharmacologic strategies

- **Vitamin C over**: 3 g orally the night before and 2 g orally twice a day after the procedure
- **N-acetylcysteine (NAC):** 1,200 mg orally twice a day on the day before and after the procedure.
- **Statins**: for cardiovascular patients - a standard of care

Endovascular

- **Strategies to minimize the use of Iodinated contrast during endovascular Aortic Procedures**:

- CO_2 angiogram
- IVUS – intravascular Ultrasound

CO_2 Angiogram

- **Experimental use since 1970**, as technology continued to improve, CO_2 evolved into a viable vascular imaging agent since the 80ths

- CO2 is a **nontoxic**, **nonflammable, buoyant**, compressible gas that has **low viscosity**

- **Endogenous**: we produce **200 – 250 cc de CO_2 per minute**

- Around 120 liters stored in human soft tissues

CO_2 Angiogram

- **Eliminated by the lungs**:
  - dissolution directly in the blood (7%),
  - bound to hemoglobin (10%),
  - or predominantly carried as a bicarbonate ion (85%)
- **No** concern for **allergy or renal toxicity**
- **Highly soluble**: 30 times greater than O_2
- Administered intravascularly, it tends to **dissolve** within a vessel in **30 seconds to 60 seconds**

CO_2 Angiogram

- **Negative** visualization
- Recommended **30 to 60 seconds** between injections
- Patients with **COPD**, sould be increased to **2 minutes**
- Due to **Rapid expansion** may cause **pain** (general anesthesia)
- **Low viscosity**: may be used with microcatether
  - 1/400 of iodinade contrast
  - Less chance of oclusion

CO_2 – Principal Indications

- Iodinated contrast allergy
- High-risk patients for contrast-induced neuropathy
- High-volume contrast procedures
- Renal transplant evaluation
- Detection of hemorrhage
- Peripheral artery occlusive disease
- Endovascular aneurysm repair
- Interventional oncology
- Venous diagnosis and intervention (central veins, hepatic/portal, IVC) TIPS
- Splenoportography

CO_2 – CONTRAINDICATIONS

- Arterial above the Diaphragm*
- **Respiratory insuficiency**
- Use of nitrous oxide general anesthesia
- Right-to- left shunts
- Pulmonary artery hypertension and a patent foramen ovale
- Pulmonar AVM
- Don’t tolerate Supine position or Trendelenburg.
- Severe aortic obstruction

CO_2 Angiogram

- The **quality and accuracy** of the image will depend on the **amount of blood displaced** by the CO_2:

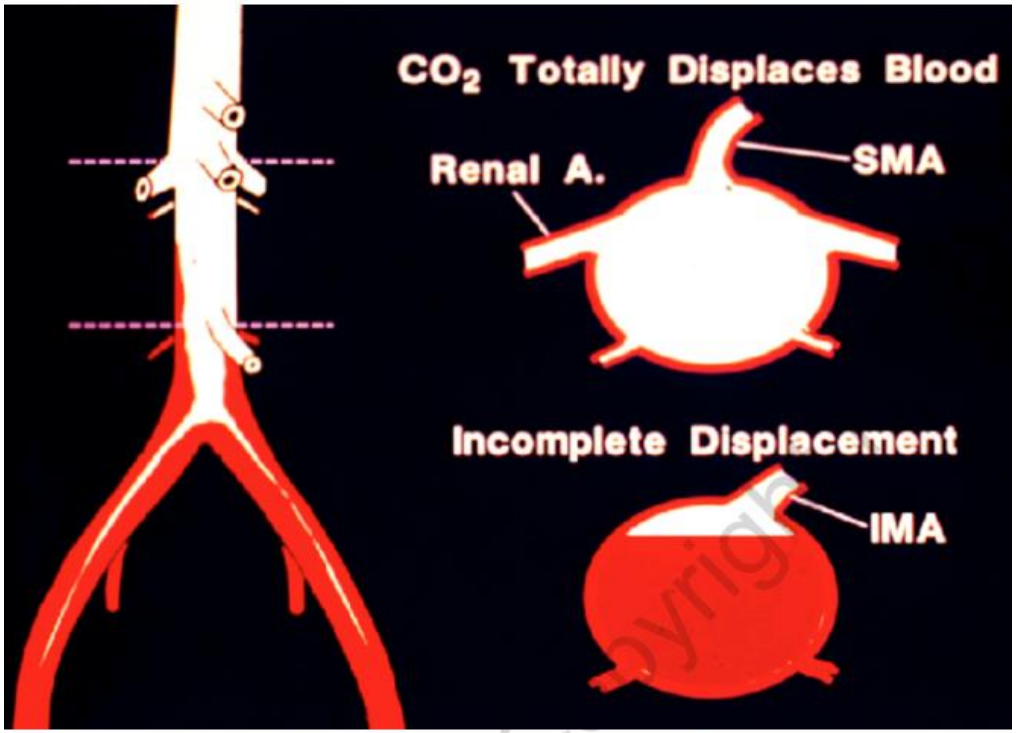

Figure 4. Carbon dioxide (white) will generate a representative image depending on the amount of blood that is displaced.

Angiografia com CO_2

- **CO_2 is lighter** than blood and **floats** anterior to it
- An advantage to **visualize anterior vessels** such as the celiac, the SMA and IMA
- Buoyancy may comprimise **analysis of Aneurysm**

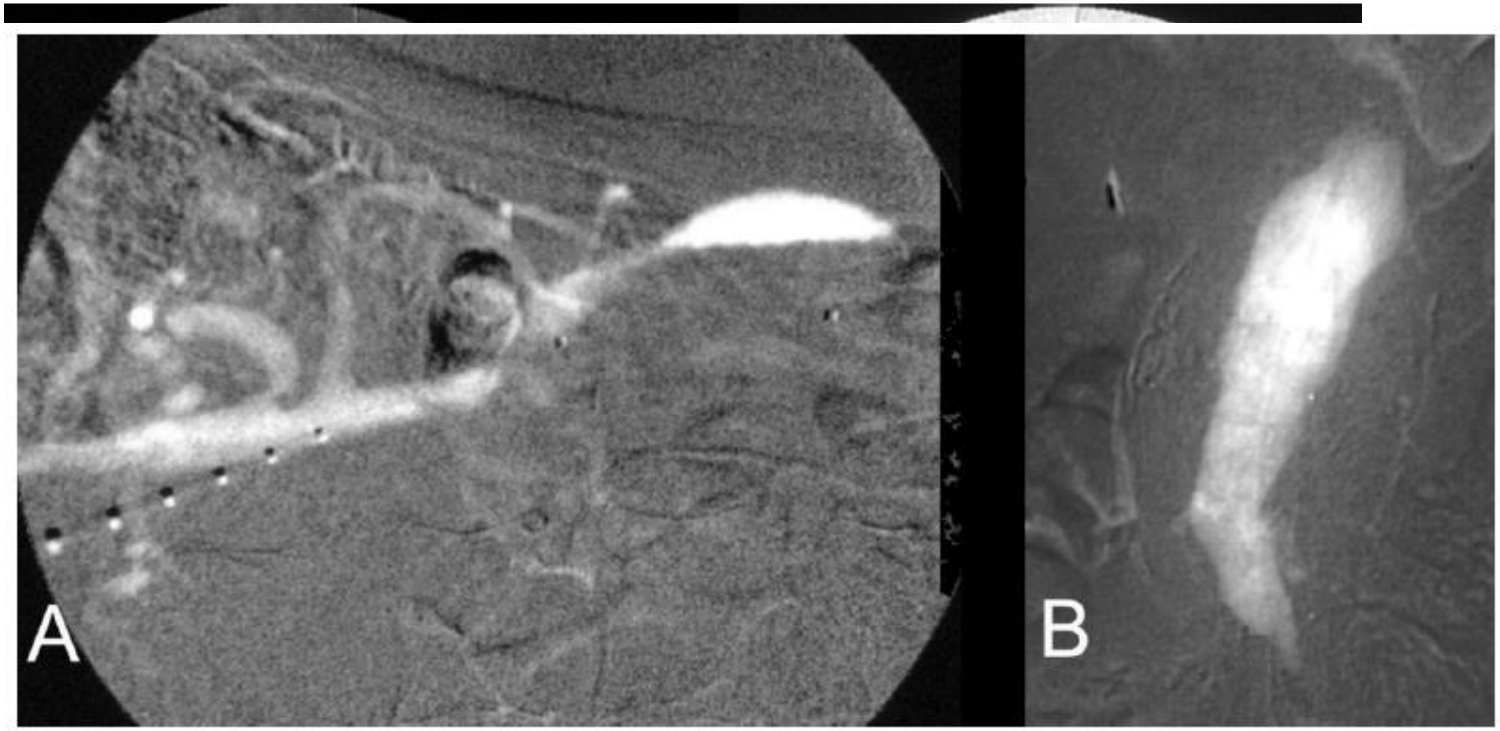

Equipments used by our team

Applications

Angiogram and treatment of dialysis access

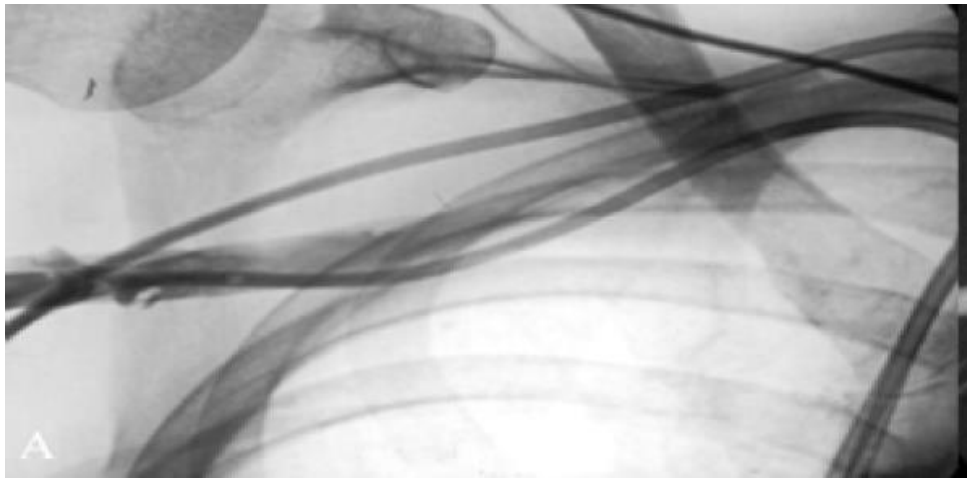

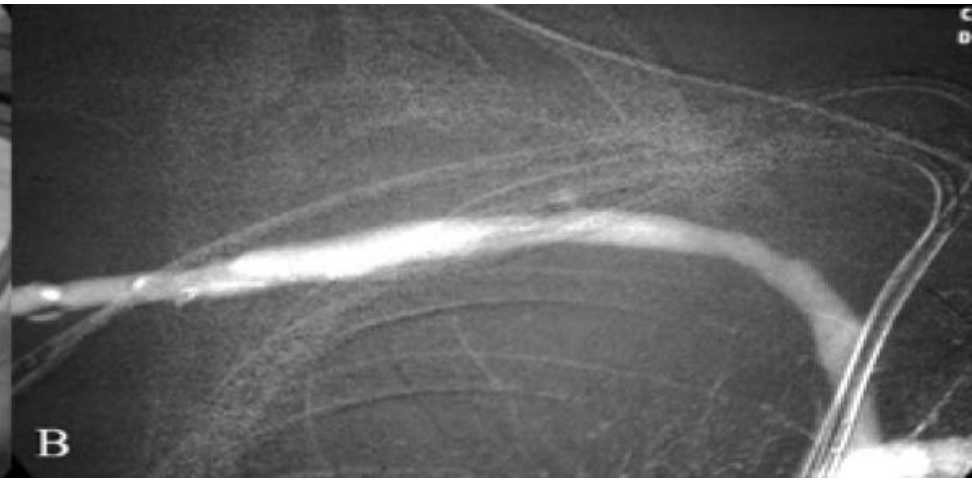

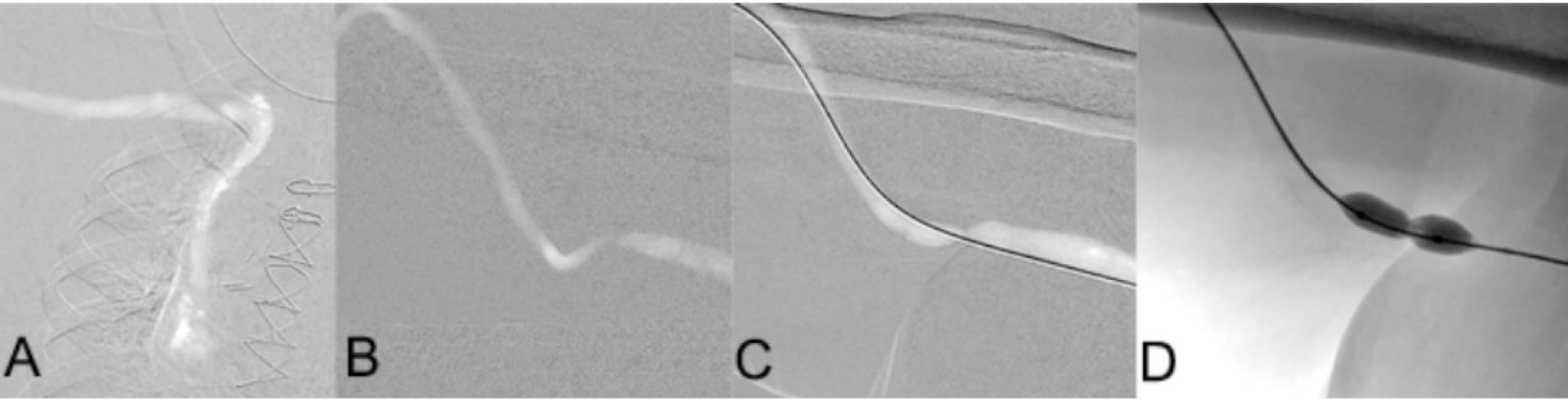

Applications

Detection of hemorrhage

Peripheral Arterial Occlusive Disease Aortic, iliac, femoral and distal

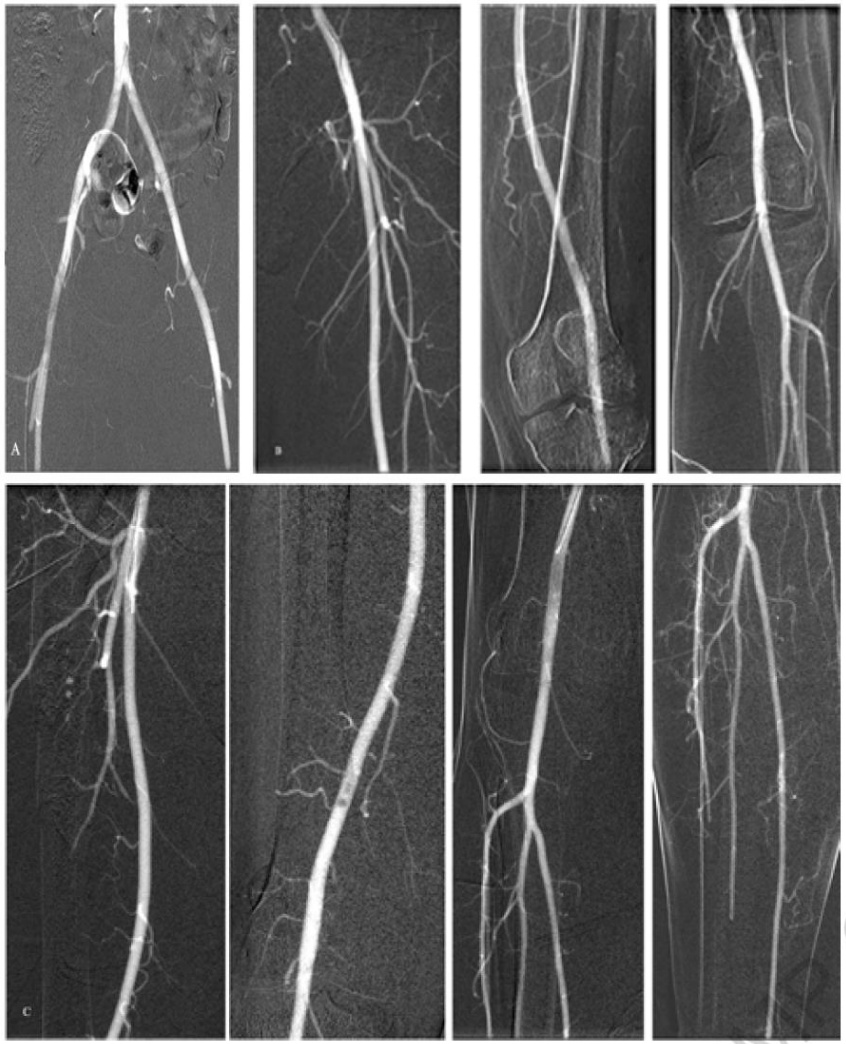

Peripheral Arterial Occlusive Disease

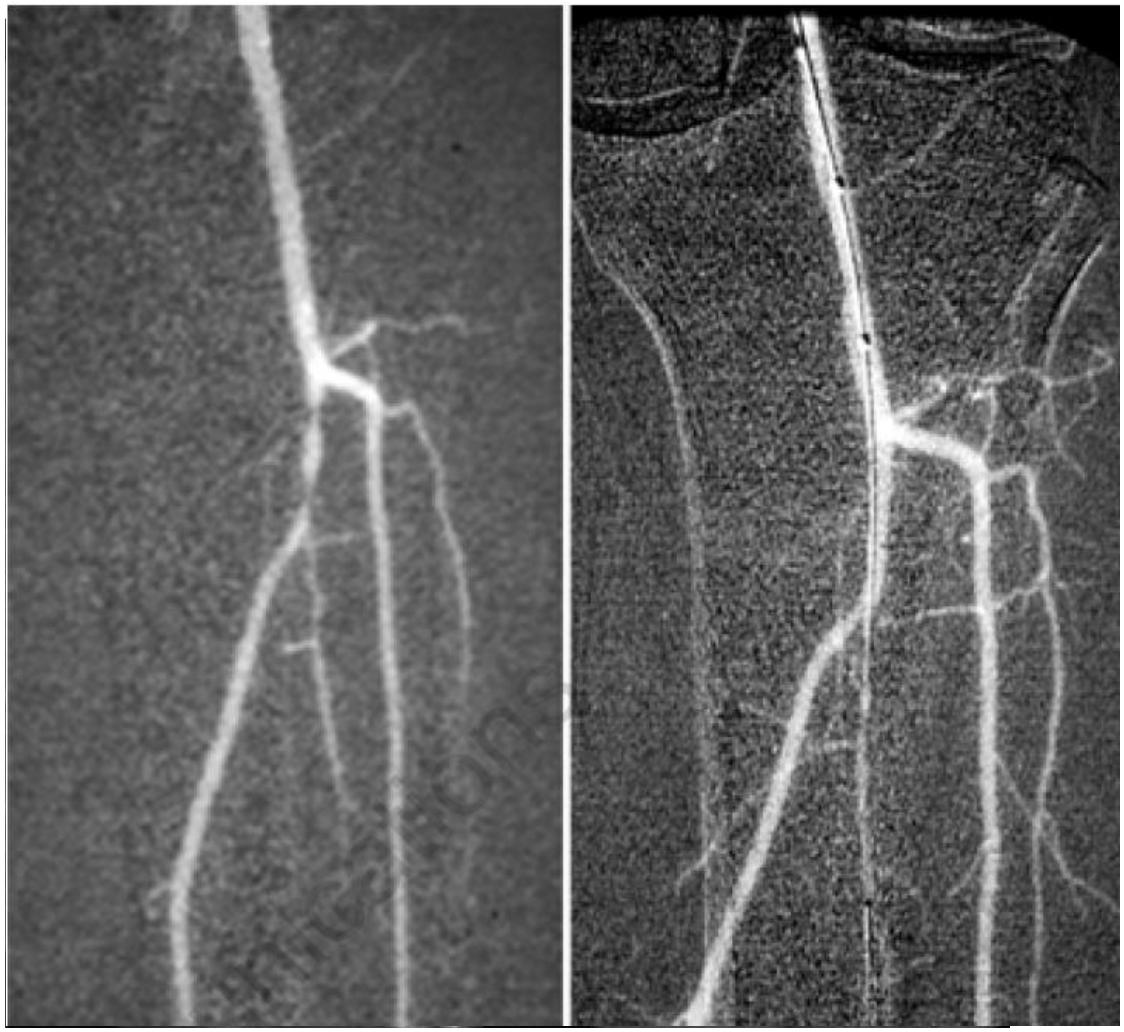

Tips:

- 0,2 ml of papaverin
- Legs elevation in 30.°

Vena Cava Filter

ENDOVASCULAR TECHNIQUES

Carbon Dioxide Digital Subtraction Angiography (CO_2 DSA): A Comprehensive User Guide for All Operators

James G. Caridi, MD, FSIR[1]; Kyung J. Cho, MD[2]; Christian Fauria, MD, MSW, MPH[1]; Navid Eghbalieh, MD[1]
From the [1]Tulane University Medical Center, New Orleans, Louisiana and the [2]University of Michigan Health System, Ann Arbor, Michigan.

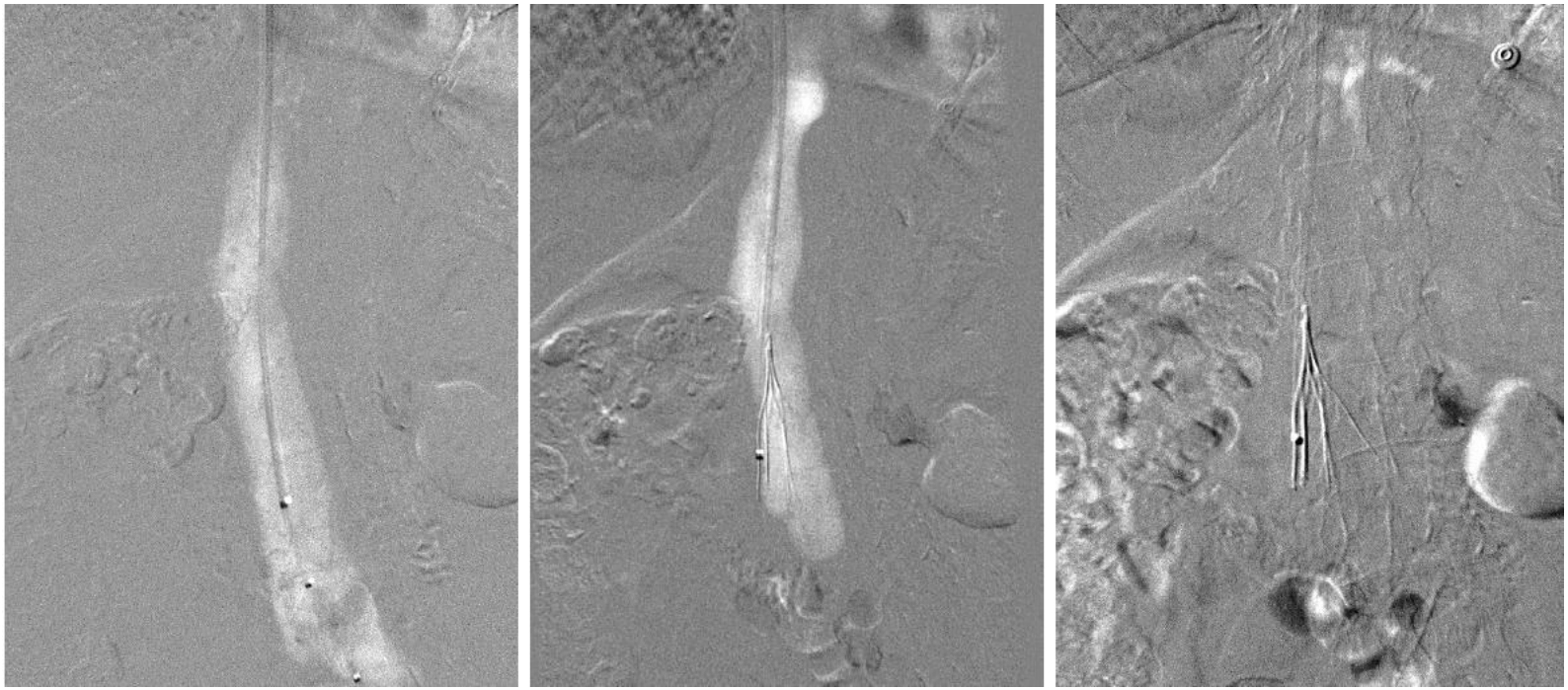

Angiorradiology

ENDOVASCULAR TECHNIQUES

Carbon Dioxide Digital Subtraction Angiography (CO_2 DSA): A Comprehensive User Guide for All Operators

James G. Caridi, MD, FSIR[1]; Kyung J. Cho, MD[2]; Christian Fauria, MD, MSW, MPH[1]; Navid Eghbalieh, MD[1]
From the [1]Tulane University Medical Center, New Orleans, Louisiana and the [2]University of Michigan Health System, Ann Arbor, Michigan.

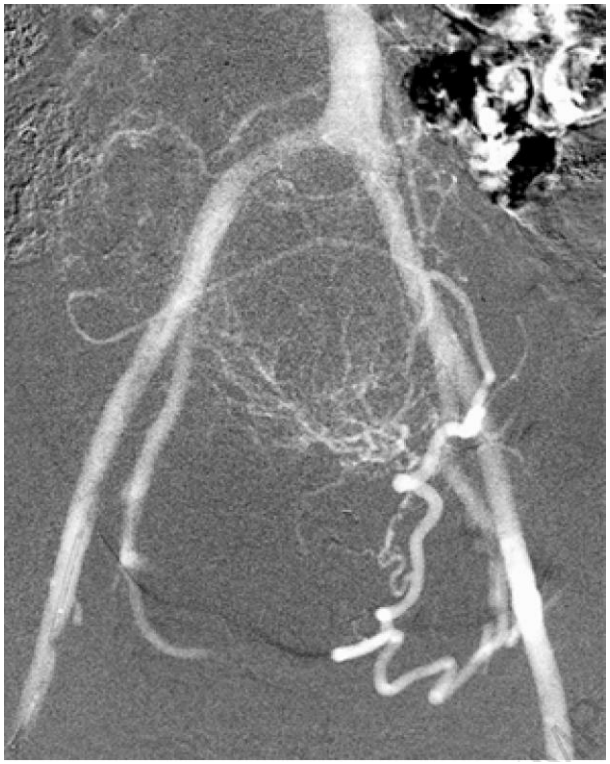

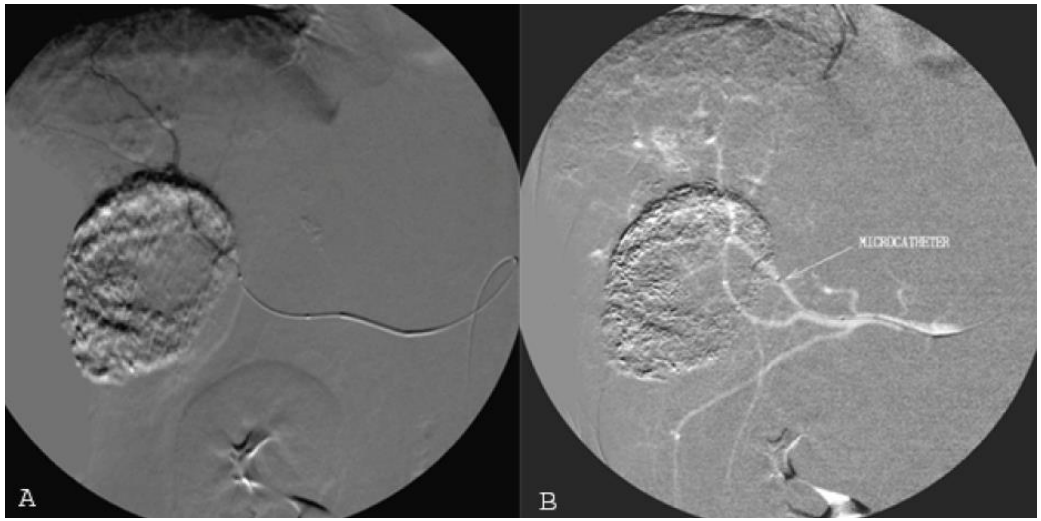

Aortic Aneurysm

20 -50 ml per injection
– association with IVUS

ENDOVASCULAR TECHNIQUES

Carbon Dioxide Digital Subtraction Angiography (CO_2 DSA): A Comprehensive User Guide for All Operators

James G. Caridi, MD, FSIR[1]; Kyung J. Cho, MD[2]; Christian Fauria, MD, MSW, MPH[1]; Navid Eghbalieh, MD[1]
From the [1]Tulane University Medical Center, New Orleans, Louisiana and the [2]University of Michigan Health System, Ann Arbor, Michigan.

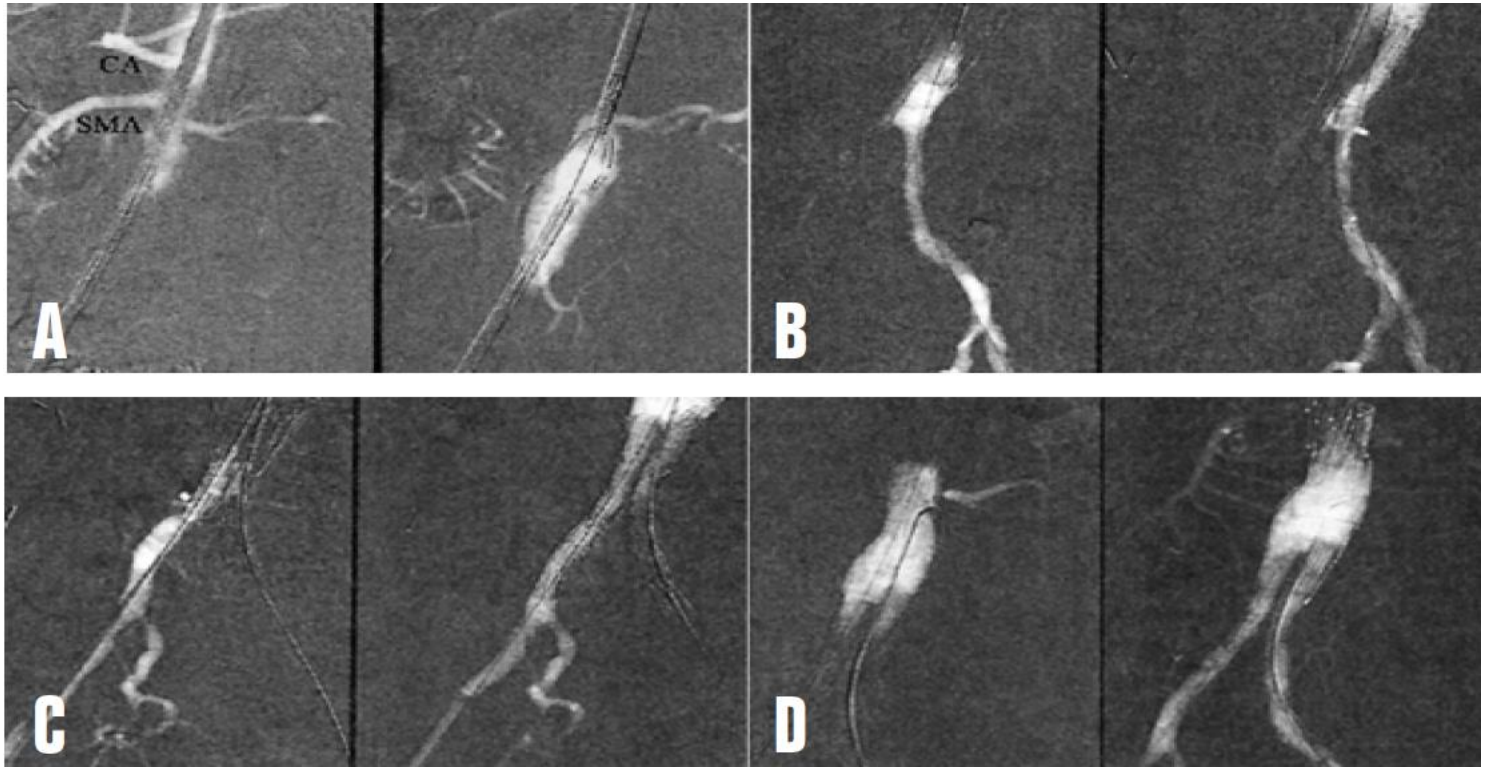

CO_2 Angiogram for EVAR

- The **incidence of renal insufficiency** in patients undergoing EVAR approximates 7% to 25%
- With **acute renal failure** occurring in 2% to 16%
- If **ARF** associated **mortality rise** to 30% to 50%

CO_2 Angiogram for EVAR

- CO_2 can be used as the **exclusive contrast agent** or in addition to **smaller volumes of iodinated contrast**

- Due of its **low viscosity** is more sensitive for detecting **endoleaks**

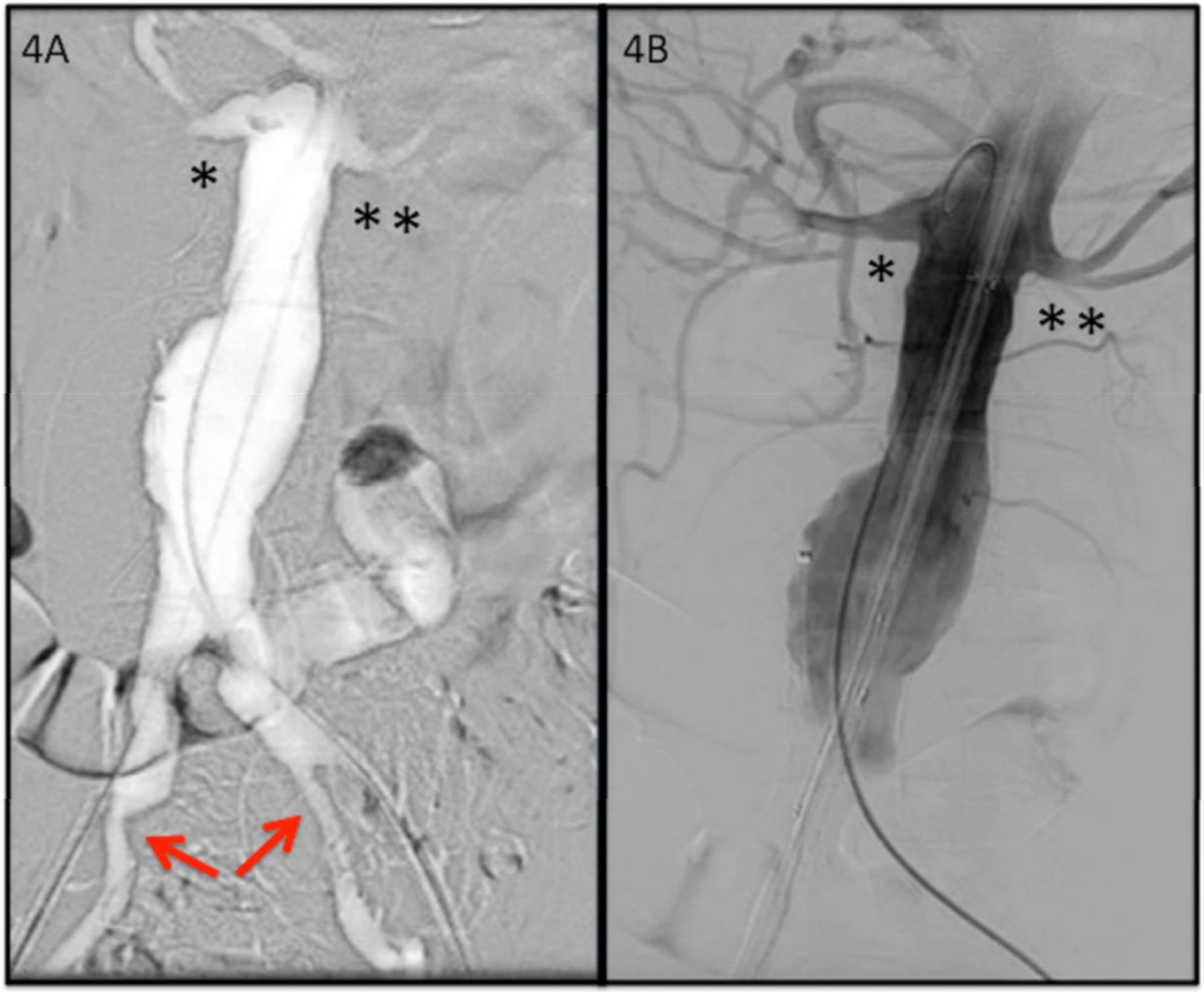
4A
*
**
4B
*
**


3A


3B

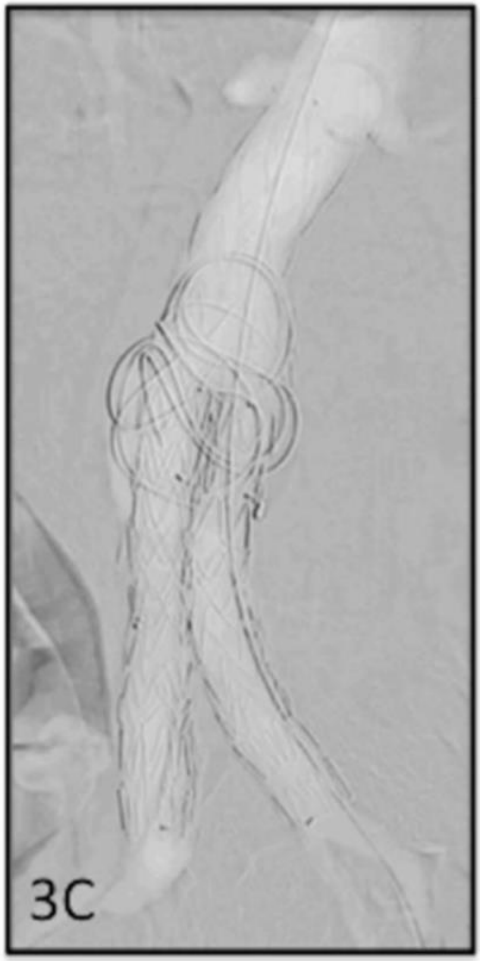
3C

Clinical Research

Midterm Outcomes of Endovascular Aortic Aneurysm Repair with Carbon Dioxide–Guided Angiography

Yuriko Takeuchi,[1] Noriyasu Morikage,[1] Yutaro Matsuno,[2] Tamami Nakamura,[1] Makoto Samura,[1] Koshiro Ueda,[1] Takasuke Harada,[1] Yoshitaka Ikeda,[2] Kotaro Suehiro,[1] Hiroshi Ito,[2] Kensuke Sakata,[2] and Kimikazu Hamano,[1] Ube and Shimonoseki, Yamaguchi, Japan

- Retrospectively reviewed
- Subjects in the CO2-EVAR group had **severe renal dysfunction (n = 27)**
- **and IC allergy (n = 4).**

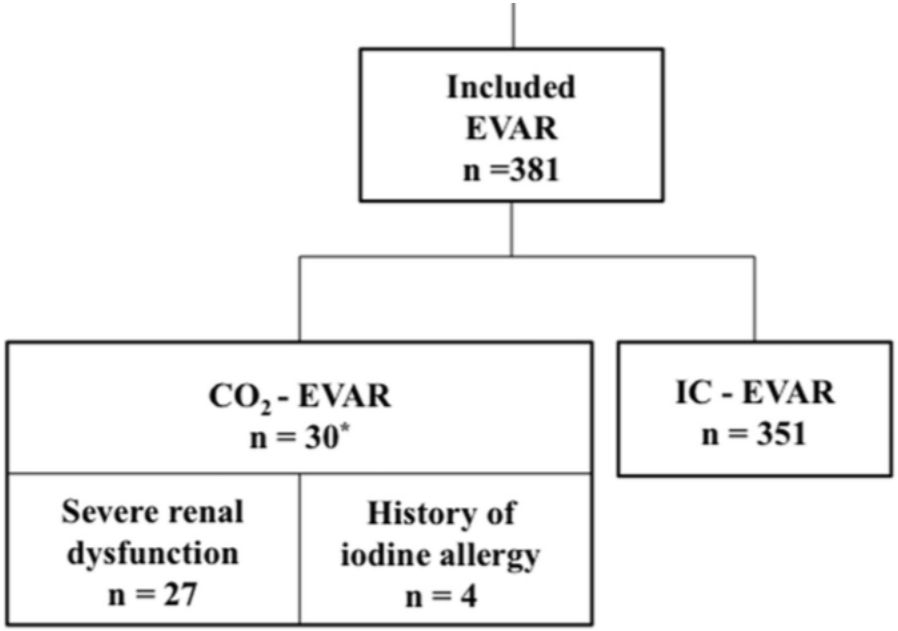

Clinical Research

Midterm Outcomes of Endovascular Aortic Aneurysm Repair with Carbon Dioxide–Guided Angiography

Yuriko Takeuchi,[1] Noriyasu Morikage,[1] Yutaro Matsuno,[2] Tamami Nakamura,[1] Makoto Samura,[1] Koshiro Ueda,[1] Takasuke Harada,[1] Yoshitaka Ikeda,[2] Kotaro Suehiro,[1] Hiroshi Ito,[2] Kensuke Sakata,[2] and Kimikazu Hamano,[1] Ube and Shimonoseki, Yamaguchi, Japan

- **Similar results:**
- The fluoroscopy time,
- operative time,
- number of stent grafts placed,
- and technical success rates

- There was no acute kidney injury

- Conclusion: CO_2-EVAR is **technically feasible** and exhibits prominent **renal protection**

Accepted Manuscript

Standardization of a carbon dioxide automated system for endovascular aortic aneurysm repair.

C. Mascoli, G.L. Faggioli, E. Gallitto, V. Vento, R. Pini, A. Vacirca, G. Indelicato, M. Gargiulo, A. Stella

PII: S0890-5096(18)30224-3

DOI: 10.1016/j.avsg.2018.01.099

- **Prospectively, 31 consecutive** patients were submitted to standard EVAR

- CO2-DSA allowed to identify the **juxta-renal landing zone** of the endograft **in 19/31 cases (61%)** and the **distal one in 31/31 (100%)**

- Completion CO2-DSA detected **type II endoleaks in 10 cases** compared with 2 of conventional contrast media.

Accepted Manuscript

Standardization of a carbon dioxide automated system for endovascular aortic aneurysm repair.

C. Mascoli, G.L. Faggioli, E. Gallitto, V. Vento, R. Pini, A. Vacirca, G. Indelicato, M. Gargiulo, A. Stella

PII: S0890-5096(18)30224-3

DOI: 10.1016/j.avsg.2018.01.099

- CO_2 EVAR procedure is effectively in the majority of cases;

- In some cases, a **single injection** of a **minimum amount of contrast** medium can be used to **overcome the renal ateries**

The Assessment of Carbon Dioxide Automated Angiography in Type II Endoleaks Detection: Comparison with Contrast-Enhanced Ultrasound

Chiara Mascoli, Gianluca Faggioli, Enrico Gallitto, Vincenzo Vento, Giuseppe Indelicato, Rodolfo Pini, Andrea Vacirca, Andrea Stella, and Mauro Gargiulo

Vascular Surgery, DIMES, University of Bologna, Policlinico S. Orsola-Malpighi, Bologna, Italy

- Twenty-one patients were enrolled in the study to identify **endoleak Type II**

- Iodinated contrast media angiography (ICM-A)
- CO_2 Angiogram (CO2-A)
- Contrast-enhanced ultrasound (CEUS)

Hindawi
Contrast Media & Molecular Imaging
Volume 2018, Article ID 7647165, 7 pages
https://doi.org/10.1155/2018/7647165

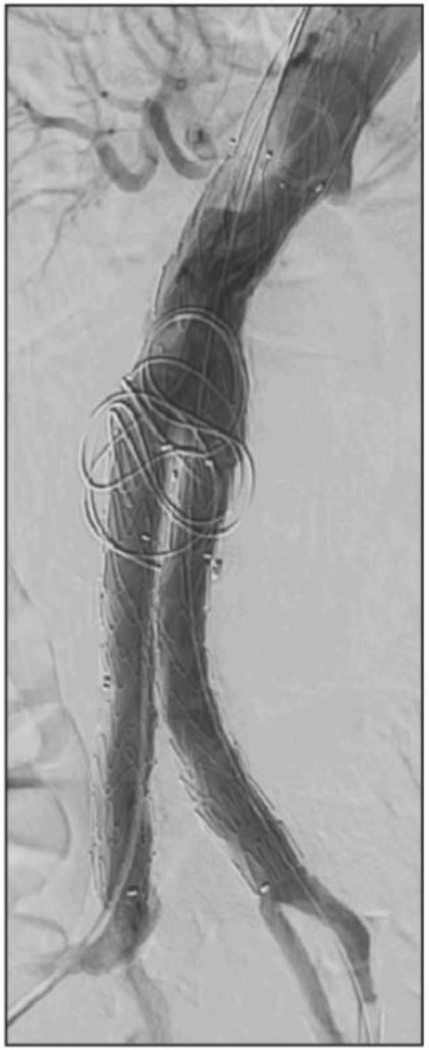

(a)

Iodinated contrast

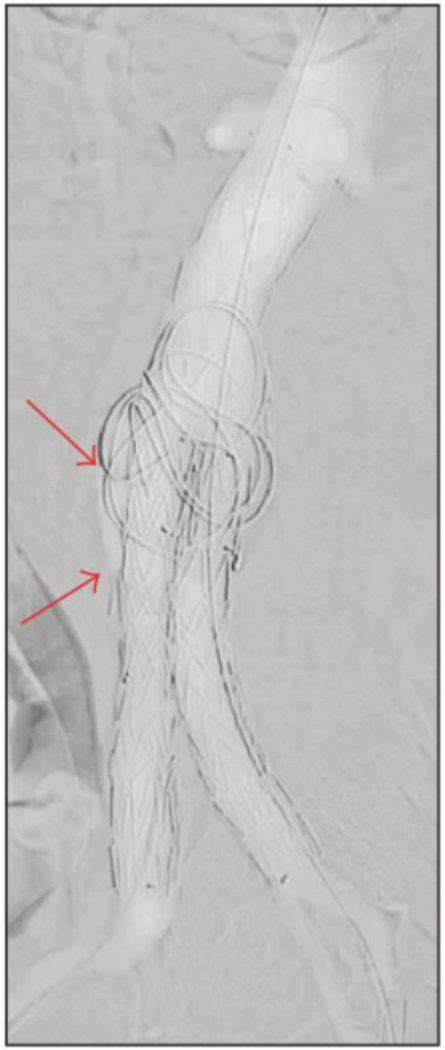

(b)

CO_2 Angiogram

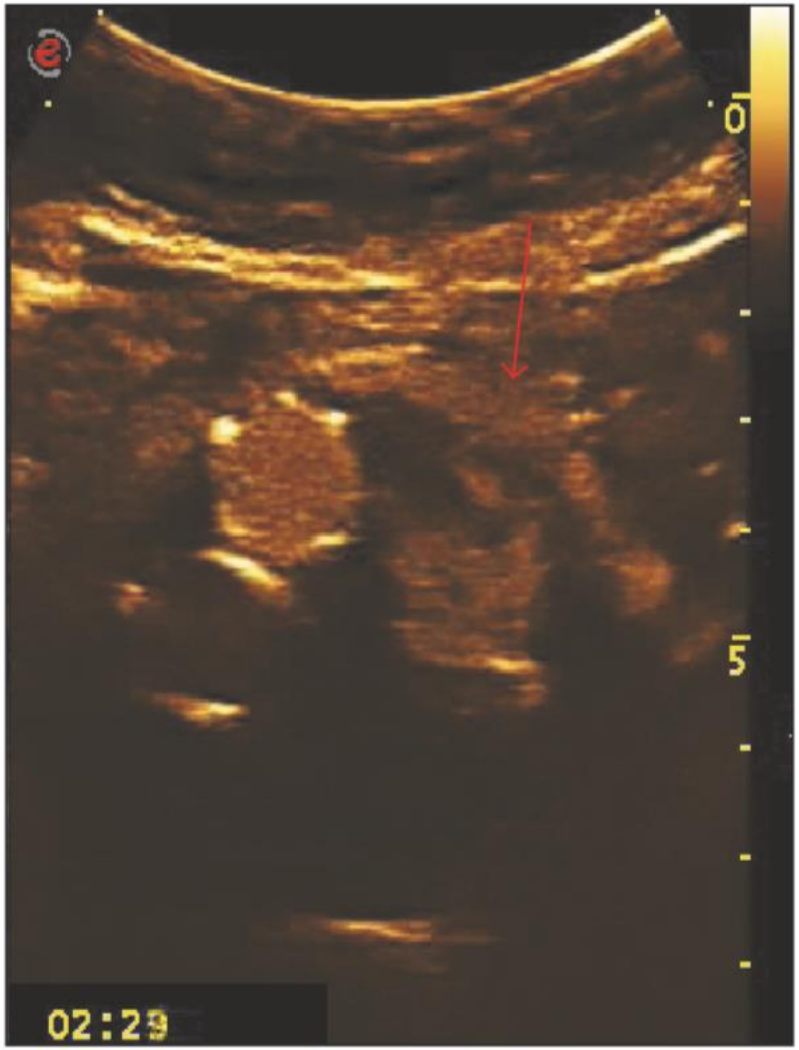

(c)

- Contrast-enhanced ultrasound (CEUS)

The Assessment of Carbon Dioxide Automated Angiography in Type II Endoleaks Detection: Comparison with Contrast-Enhanced Ultrasound

Chiara Mascoli, Gianluca Faggioli, Enrico Gallitto, Vincenzo Vento, Giuseppe Indelicato, Rodolfo Pini, Andrea Vacirca, Andrea Stella, and Mauro Gargiulo

Vascular Surgery, DIMES, University of Bologna, Policlinico S. Orsola-Malpighi, Bologna, Italy

Table 4: Type II endoleak detected by CO_2-A, ICM-A, and CEUS.

ID	CO_2-A	ICM-A	CEUS
# 5	√	–	√
# 9	√	–	–
# 14	√	–	√
# 16	√	–	–
# 17	√	√	√
# 18	√	–	–
# 21	√	–	√

ID: patient series number; √: type II endoleak presence; –: type II endoleak absence.

CO2-A is safe and effective method for ELII detection in EVAR, with a significantly higher agreement with CEUS if compared with ICM-A

IVUS- Ultrassom intravascular

- IVUS provides **real-time data** during aortic interventions, which results in appropriate **diagnosis, graft selection, and deployment**.

- Information that **can reduce** the **contrast load**

Pearce, Benjamin J, e William D Jordan Jr. "Using IVUS during EVAR and TEVAR: improving patient outcomes". Seminars in vascular surgery 22, no 3 (setembro 2009): 172–180.

IVUS- Ultrassom intravascular

- Also can assess the adequacy of **graft apposition** after deployment

- For **type I and III endoleaks**, the IVUS is a valuable tool to assess conformation of the device within the proximal neck and graft apposition

- **Aortic dissections**: utility in defining the often confusing series of **entry and reentry sites**

Pearce, Benjamin J, e William D Jordan Jr. "Using IVUS during EVAR and TEVAR: improving patient outcomes". Seminars in vascular surgery 22, no 3 (setembro 2009): 172–180.

IVUS: Phillips/Volcano and Boston ScientiC



	French	Fio Guia (in)	Frequência	Diâmetro	Especificações
Eagle Eye	2,9	0,014, Rx	20 MHz	16 mm	▸ Gray Scale ▸ CromaFlow ▸ Histologia Virtual
Visions PV 0.018	3,4	0,018, Rx	20 MHz	24 mm	▸ Gray Scale ▸ CromaFlow
Visions PV 0.035	8,2	0,038, OTW	10 MHz	60 mm	▸ Gray Scale

Measurements

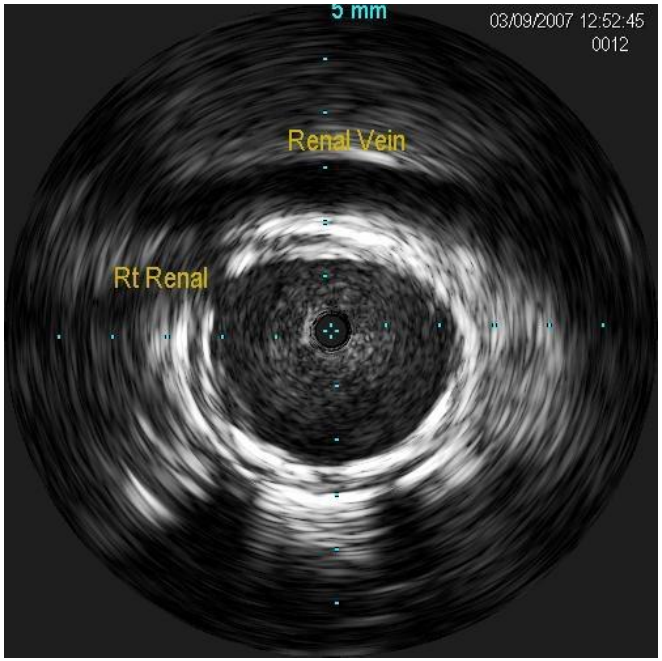

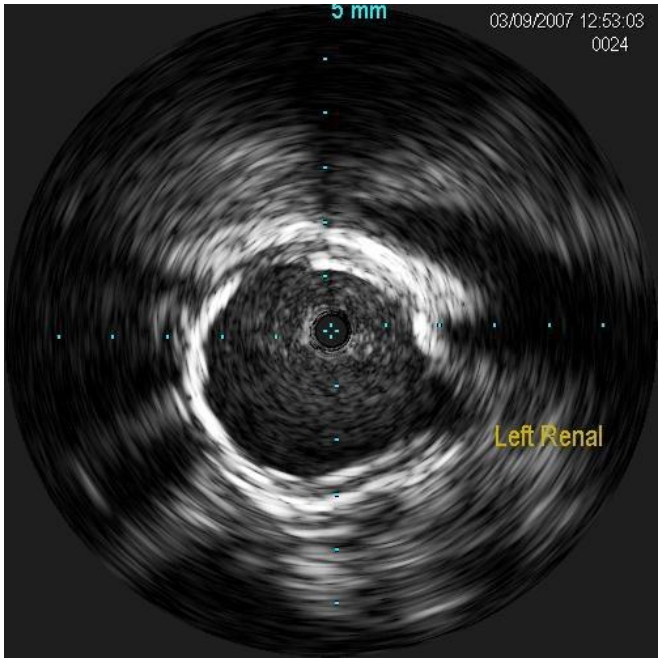

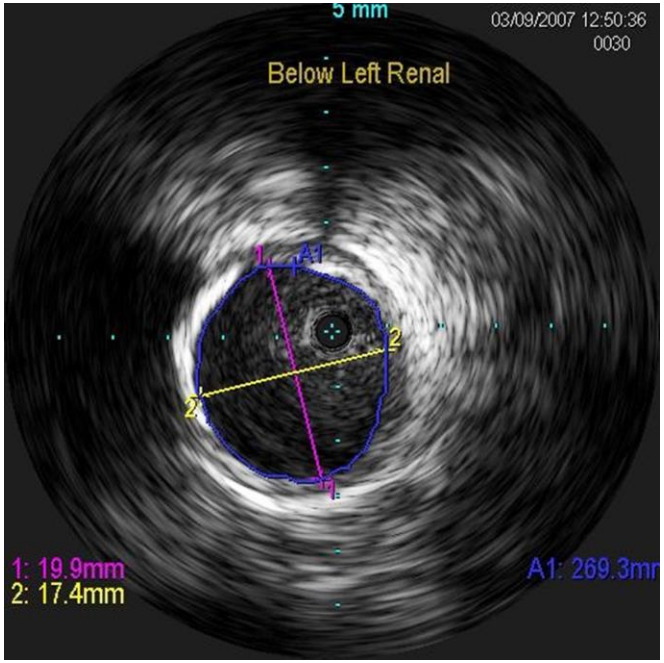

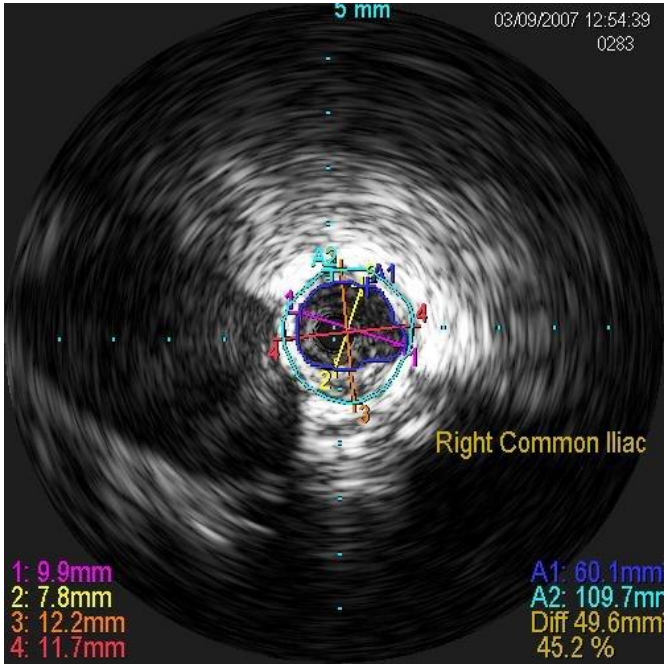

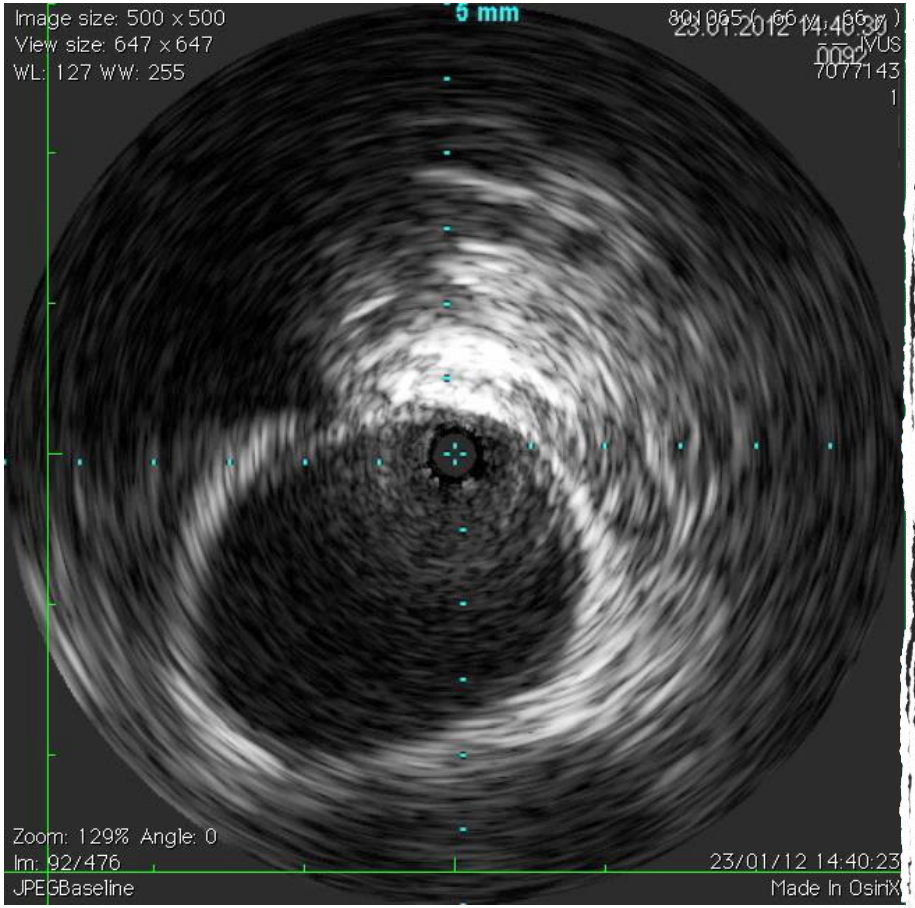
Image size: 500 x 500
View size: 647 x 647
WL: 127 WW: 255
5 mm
23.01.2012 14:40:30
IVUS
0092
7077143
1
Zoom: 129% Angle: 0
Im: 92/476
23/01/12 14:40:23
JPEGBaseline
Made In OsiriX

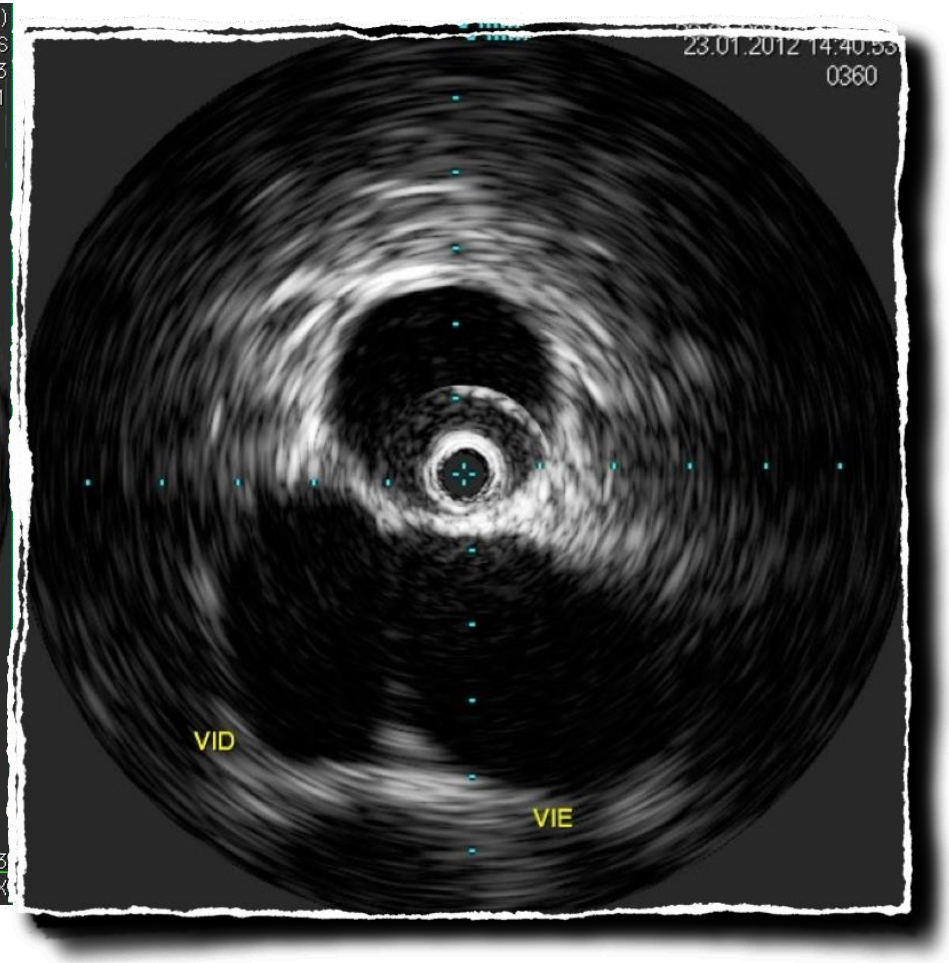
23.01.2012 14:40:53
0360
VID
VIE

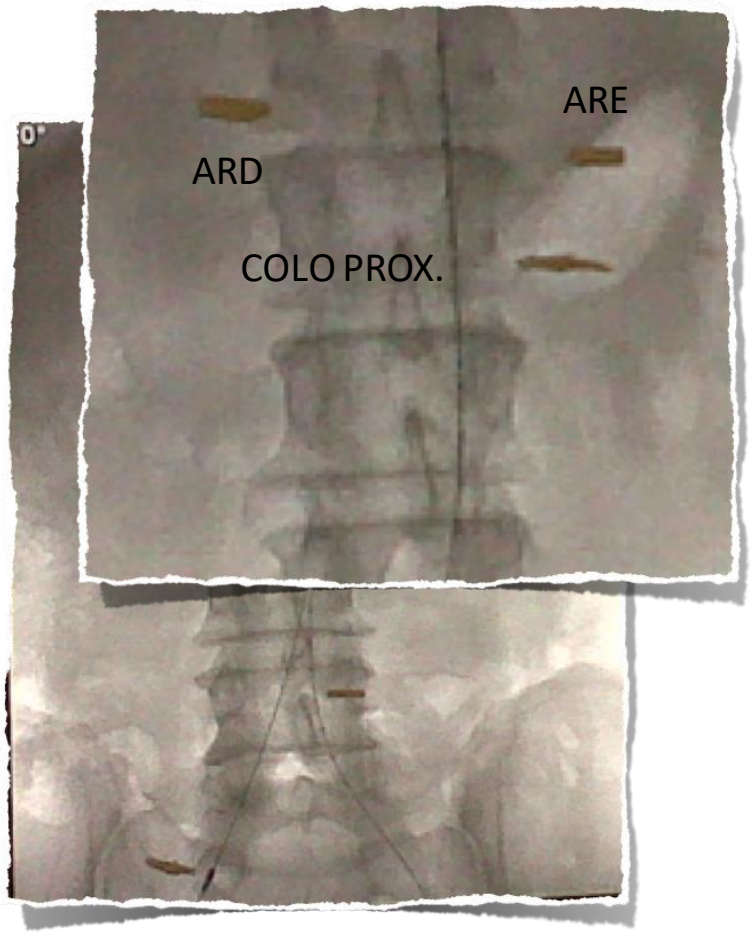
ARE
ARD
COLO PROX.

ANNALS of VASCULAR SURGERY
International Journal of Vascular Surgery

Endovascular Aortic Aneurysm Repair in Patients with Renal Dysfunction or Severe Contrast Allergy: Utility of Imaging Modalities without Iodinated Contrast

Ruth L. Bush, MD,[1] Peter H. Lin, MD,[2] Charles C. Bianco, MD,[1] Alan B. Lumsden, MD,[2] Annette B. Gunnoud, RVT,[3] Thomas T. Terramani, MD,[3] William T. Brinkman, MD,[3] Louis G. Martin, MD,[3] and Victor J. Weiss, MD,[3] Tallahassee, Florida, Houston, Texas, and Atlanta, Georgia

Ann Vasc Surg 2002; 16: 537-544
DOI: 10.1007/s10016-001-0273-7

Published online: 21 August 2002

- Good results n the **20 patients for EVAR,** despite the presence of renal dysfunction or severe contrast allergy

- Non-iodinated contrast-based imaging modalities (IVUS, CO_2 and MRA/Gad)

Table III. Imaging modalities used in preoperative assessment, endograft implantation, and follow-up

	Modality	*n*
Preoperative assessment	Gadolinium-enhanced MRA	7
	Non-contrast CT	10
	CO_2 aortography	7
Intraoperative assessment	IVUS	13
	Gadolinium aortography	20
Postoperative surveillance	Duplex ultrasound	19

Aortic Disease

Penetrating ulcer

Intramural Hematoma

Aortic Trauma

Aortic Dissection

Thoracic aorta trauma

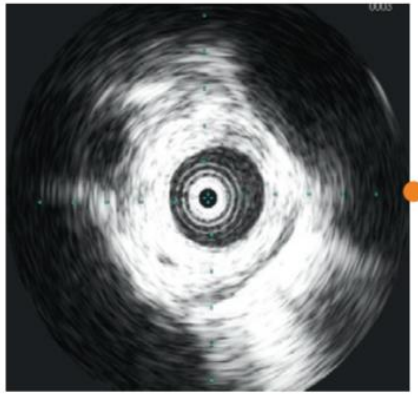

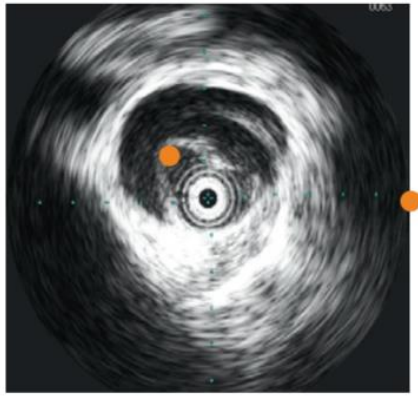

Dissection

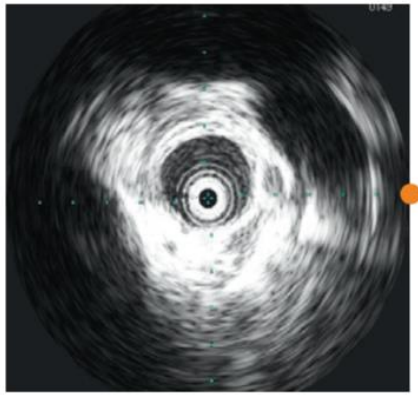

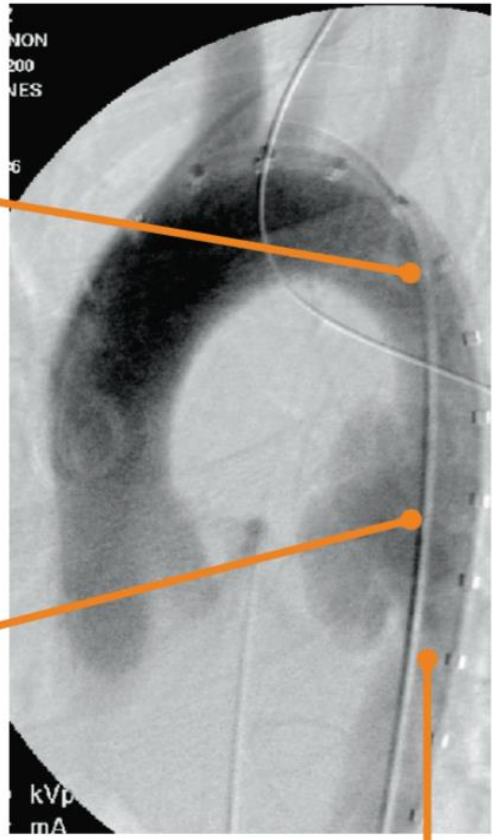

Angiogram of thoracic aorta with corresponding IVUS images

Intramural Hematoma

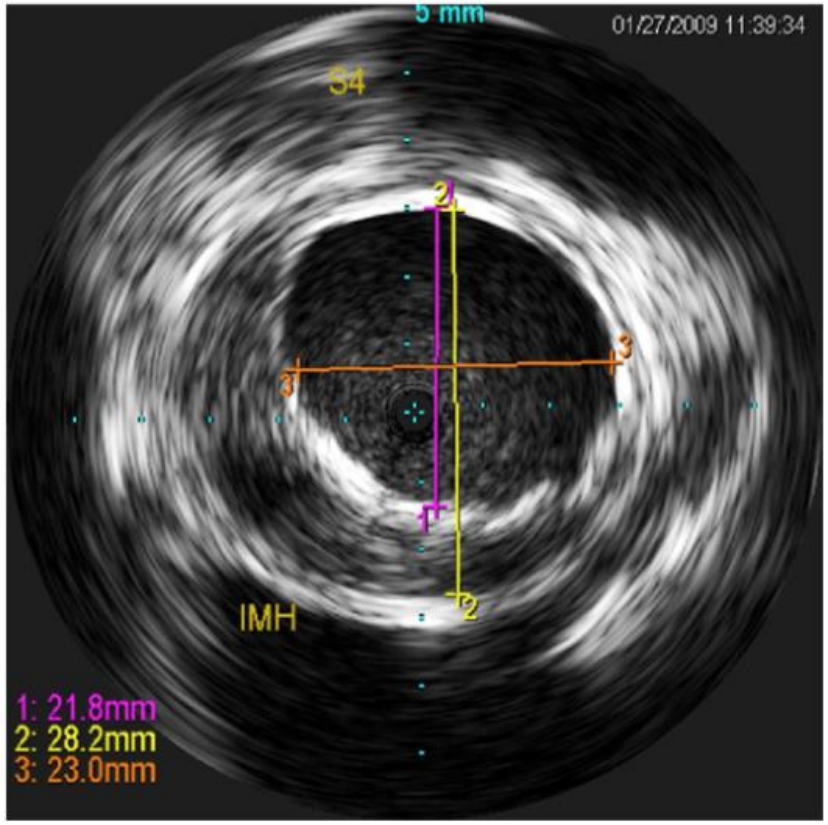

Type B Disseccion

- IVUS can confirm true lumen access and precisely define the proximal entry site
- Branches involved
- Oversizing appropriately
- Confirm technical success
- Less Contrast and fluoroscopy time

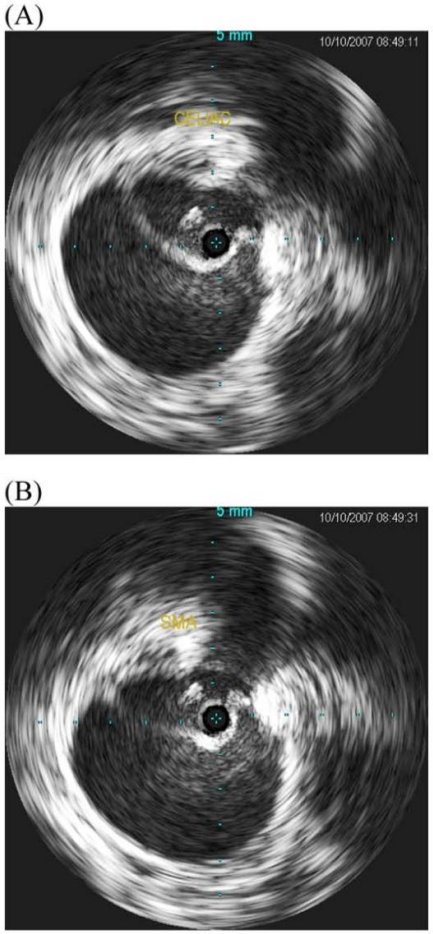

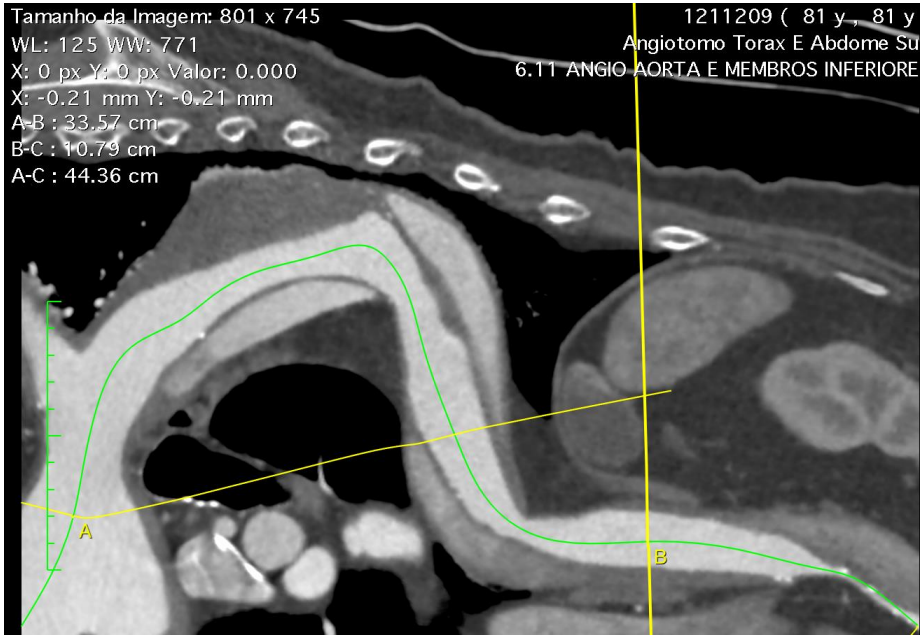
Tamanho da Imagem: 801 x 745
WL: 125 WW: 771
X: 0 px Y: 0 px Valor: 0.000
X: -0.21 mm Y: -0.21 mm
A-B : 33.57 cm
B-C : 10.79 cm
A-C : 44.36 cm
1211209 (81 y , 81 y
Angiotomo Torax E Abdome Su
6.11 ANGIO AORTA E MEMBROS INFERIORE
A
B


S-I: -90°

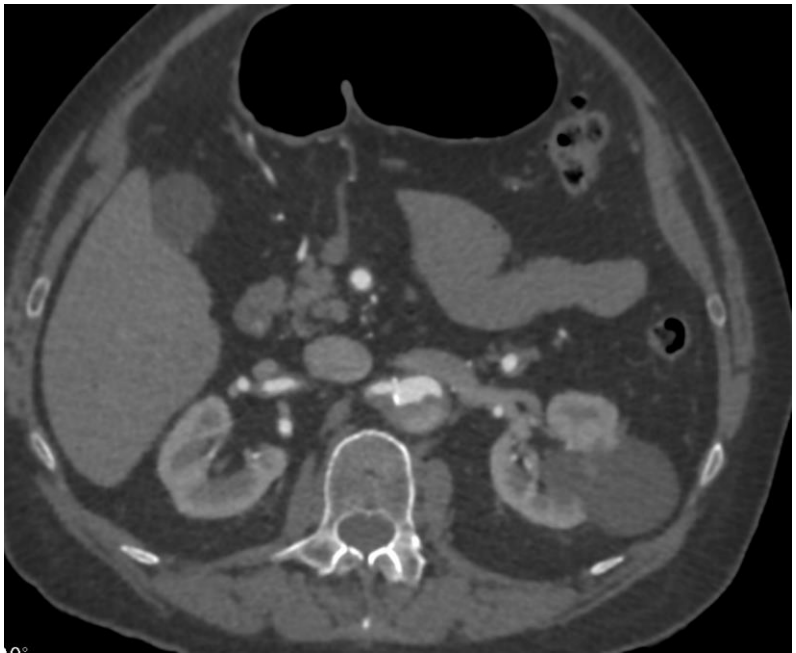


-90°

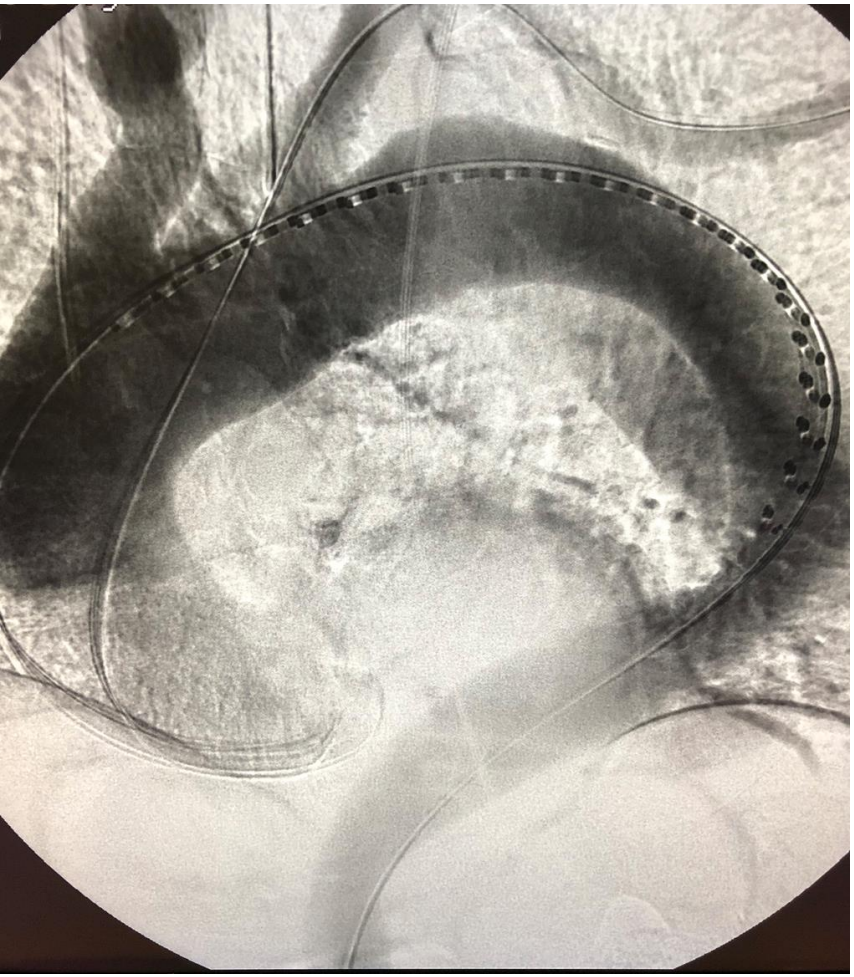

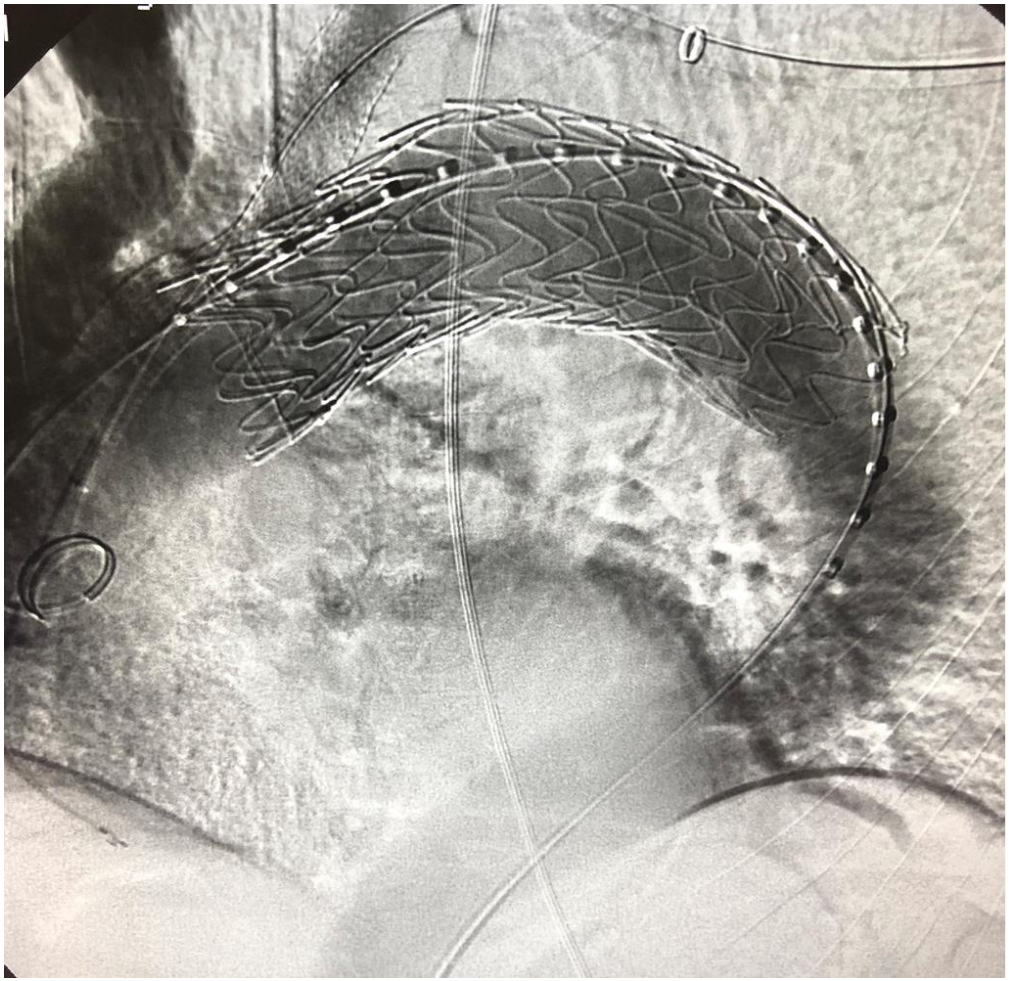

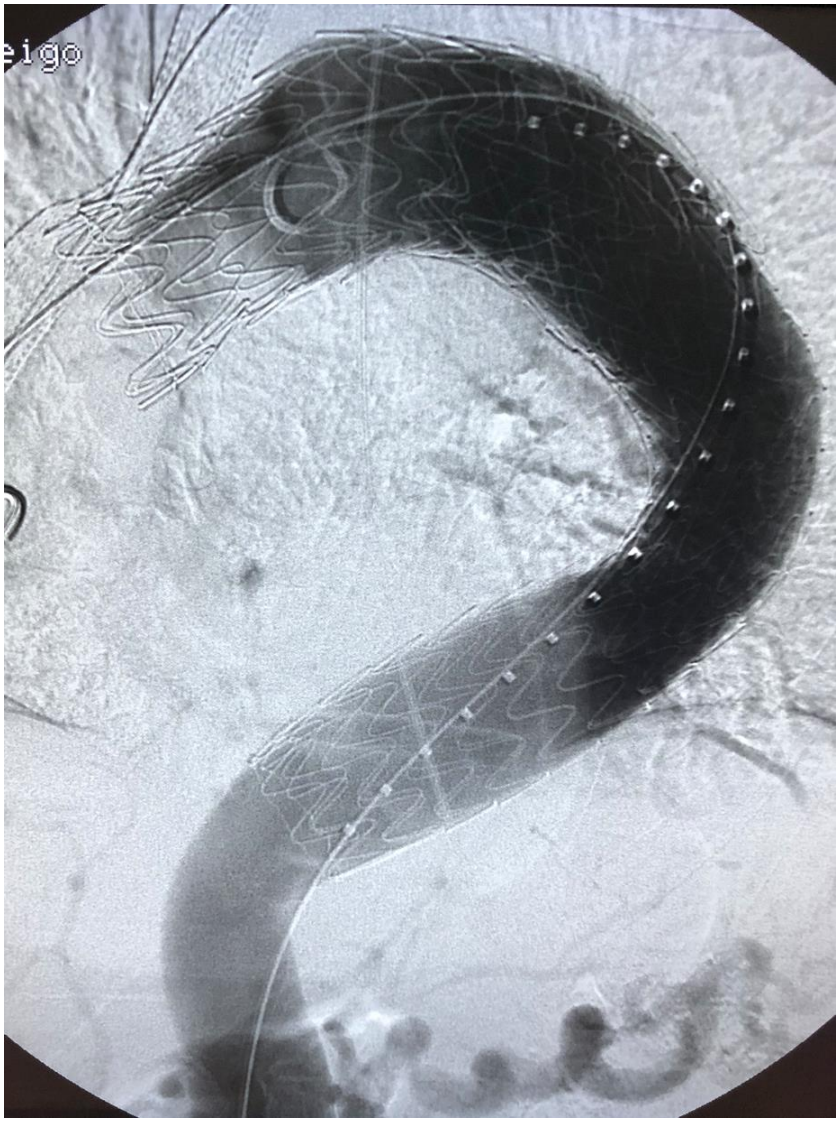
eigo


Leigo

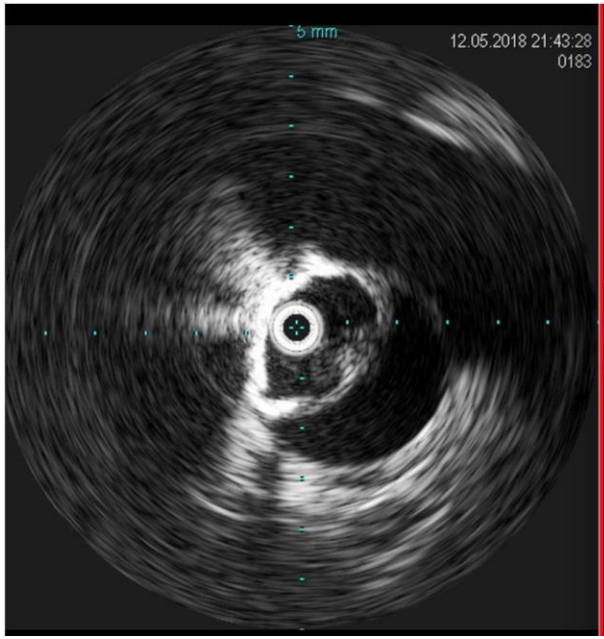
5 mm
12.05.2018 21:43:28
0183

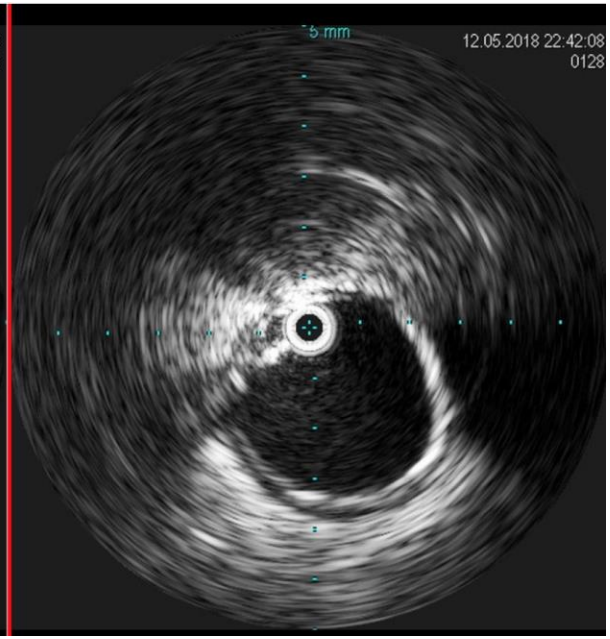
5 mm
12.05.2018 22:42:08
0128

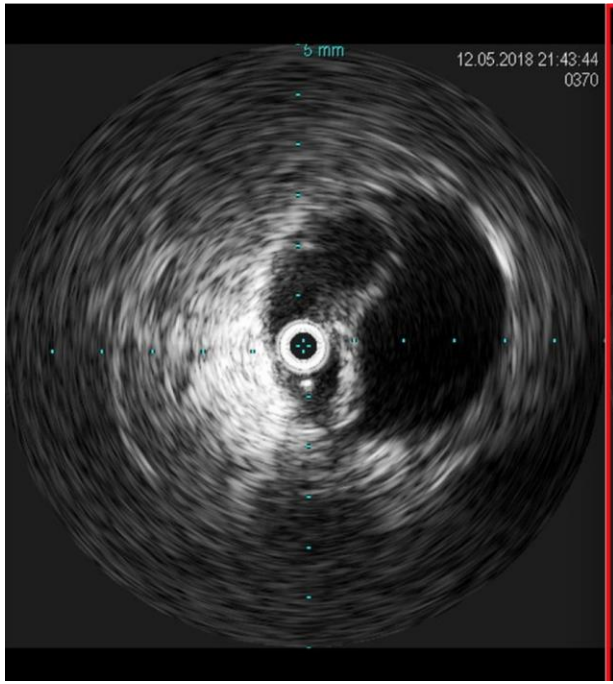
5 mm
12.05.2018 21:43:44
0370

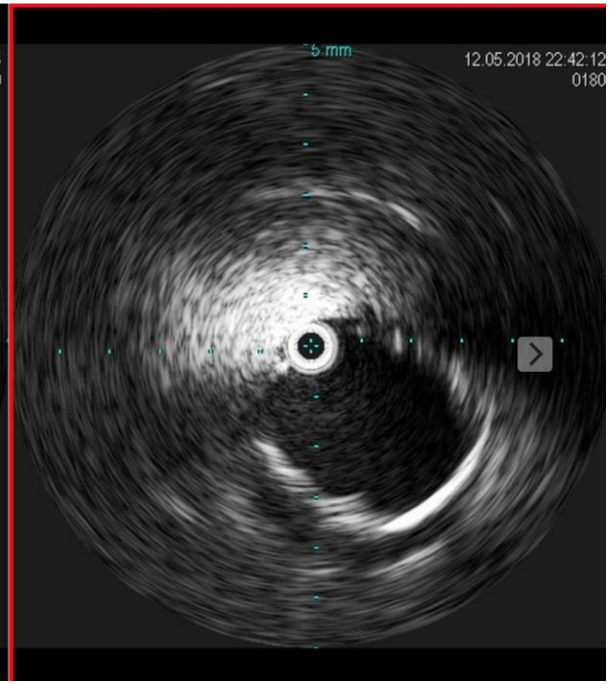
5 mm
12.05.2018 22:42:12
0180

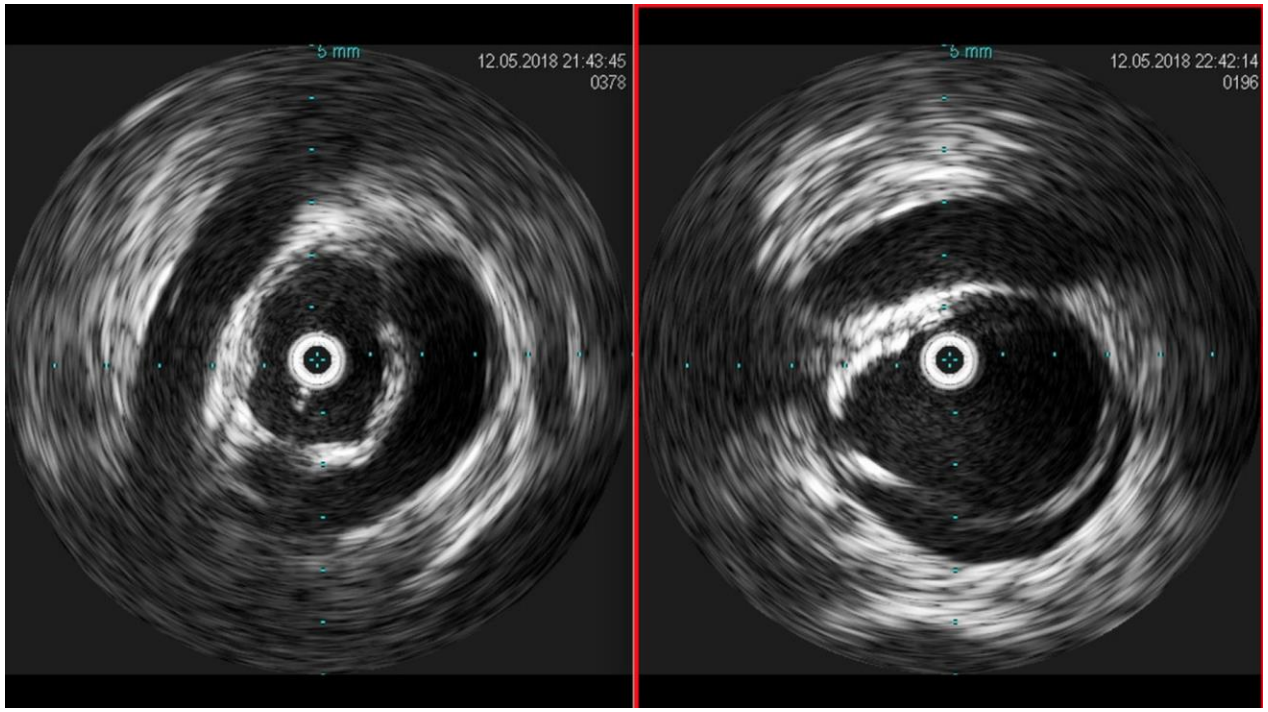
5 mm
12.05.2018 21:43:45
0378
5 mm
12.05.2018 22:42:14
0196

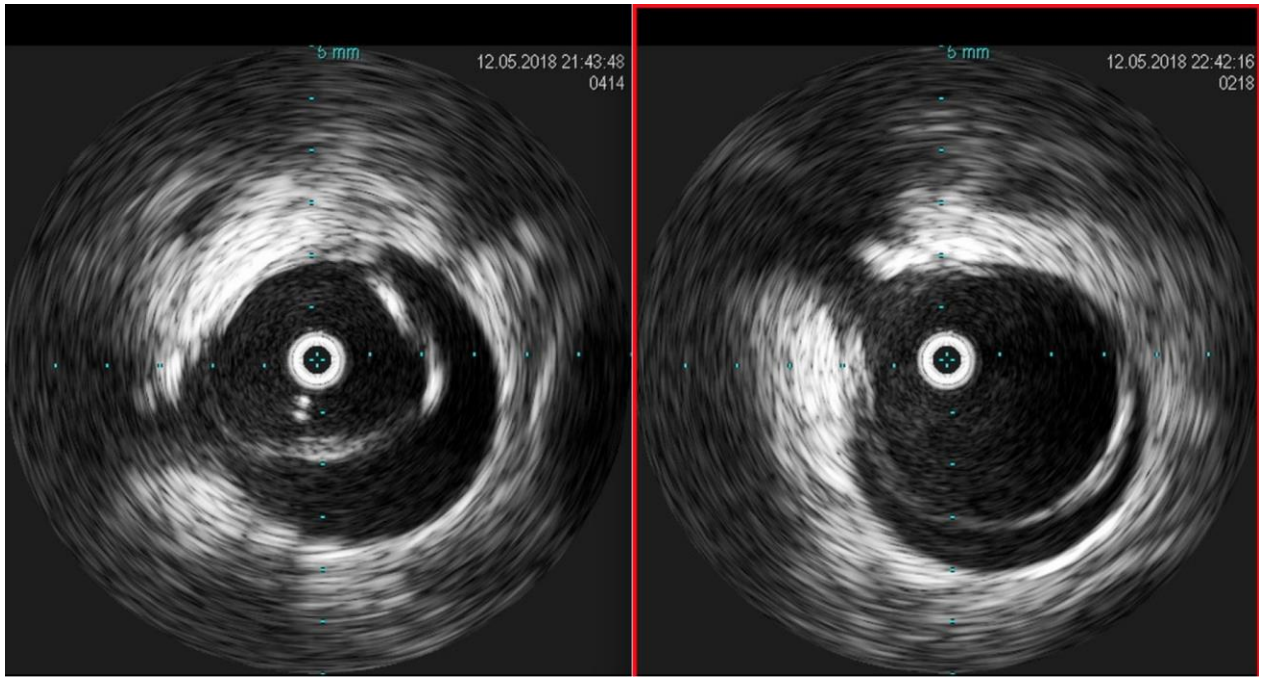
5 mm
12.05.2018 21:43:48
0414
5 mm
12.05.2018 22:42:16
0218

Type III Endoleak

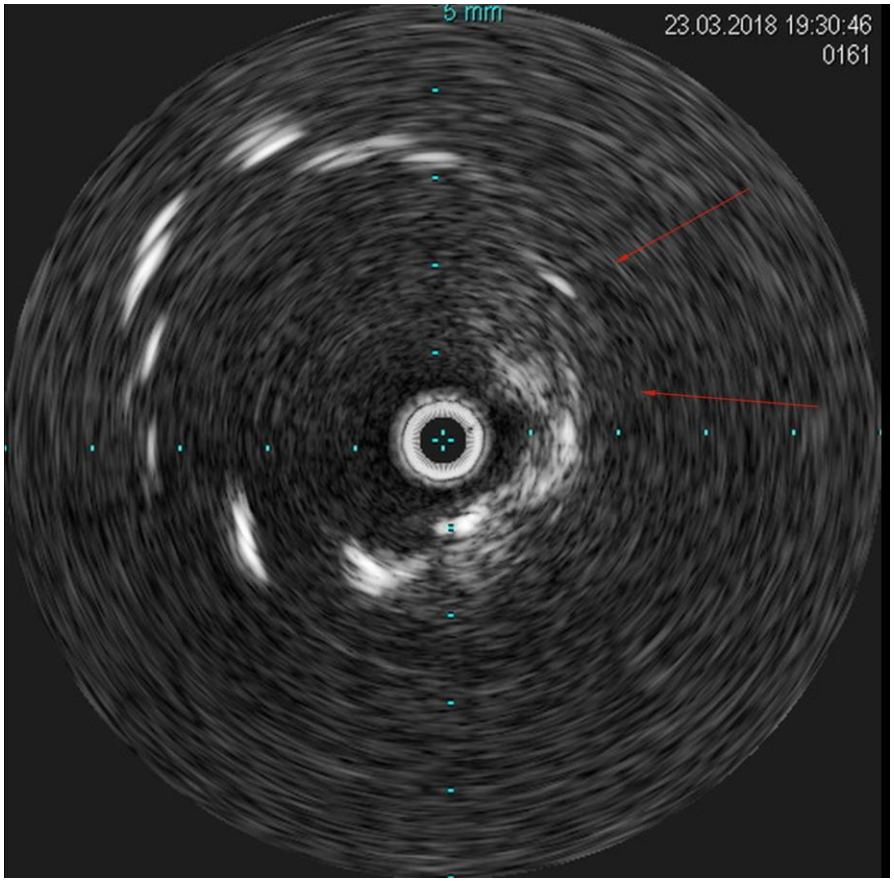

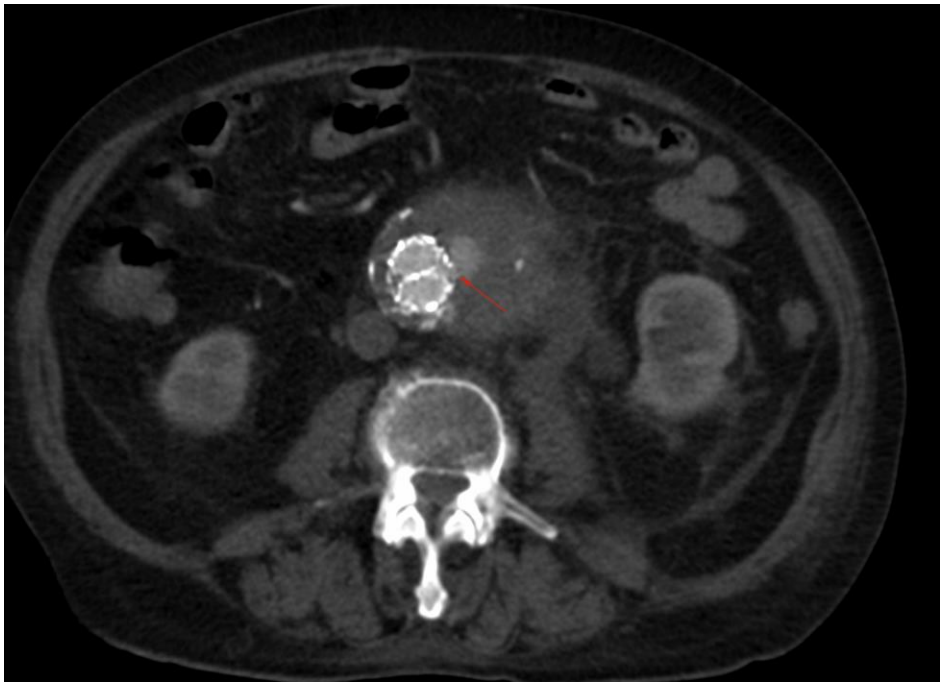

Endoleak tipo III

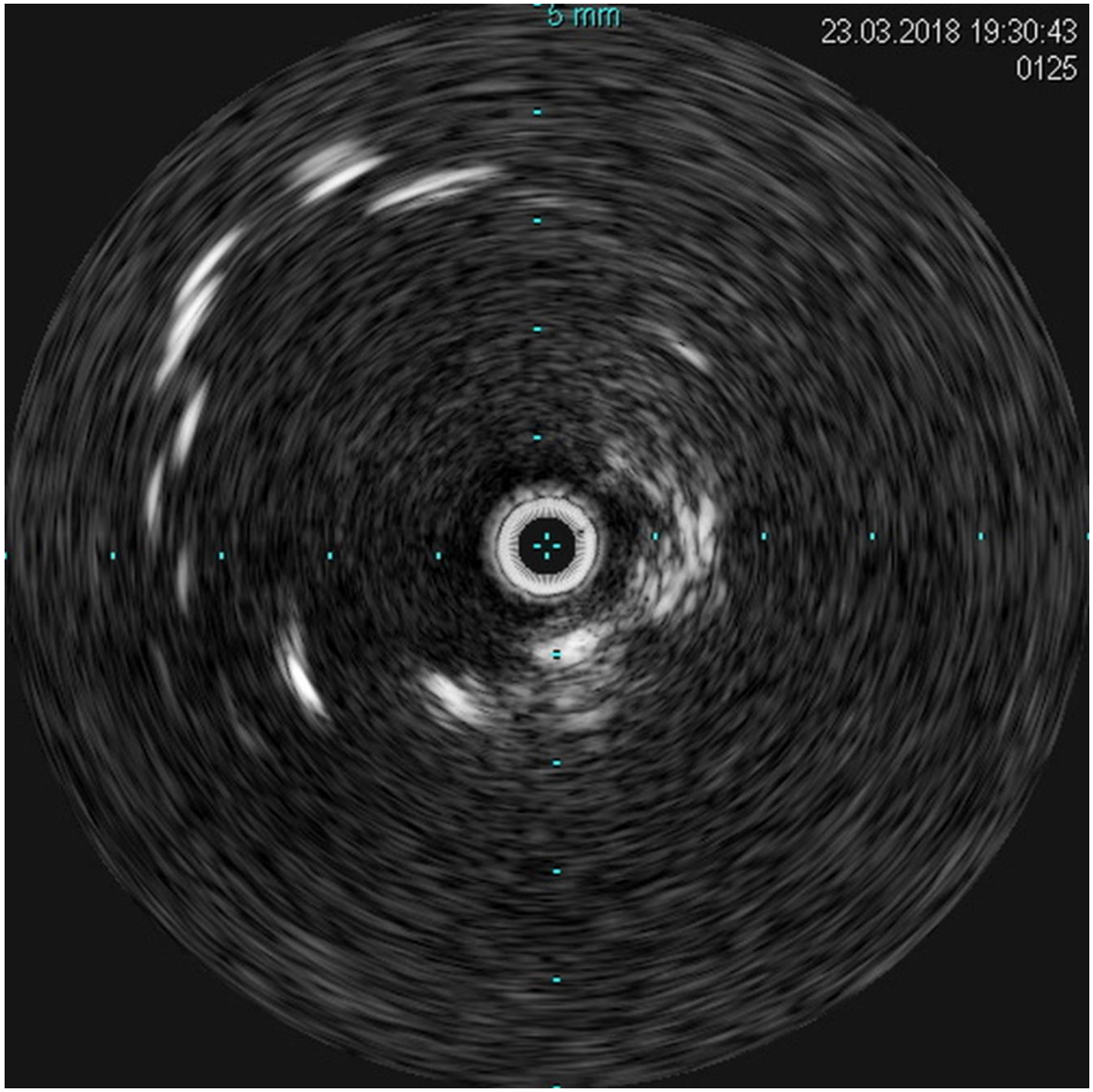

Conclusion

- **CO_2 Angiogram and IVUS** are **effective tools** to minimize the effect of media contrast in aortic procedures
- More studies are needed to define if **indications** should be **expanded**
- CO_2 can be used only in **abdominal aorta**
- **IVUS is essential** for **complex aortic disease**

Thank you


SEE YOU NEXT YEAR
ScIENCE2019
4º Simpósio Internacional de Cirurgia Endovascular
São Paulo | june 13 - 15