Open Repair of Type A Aortic Dissection: The Penn Approach

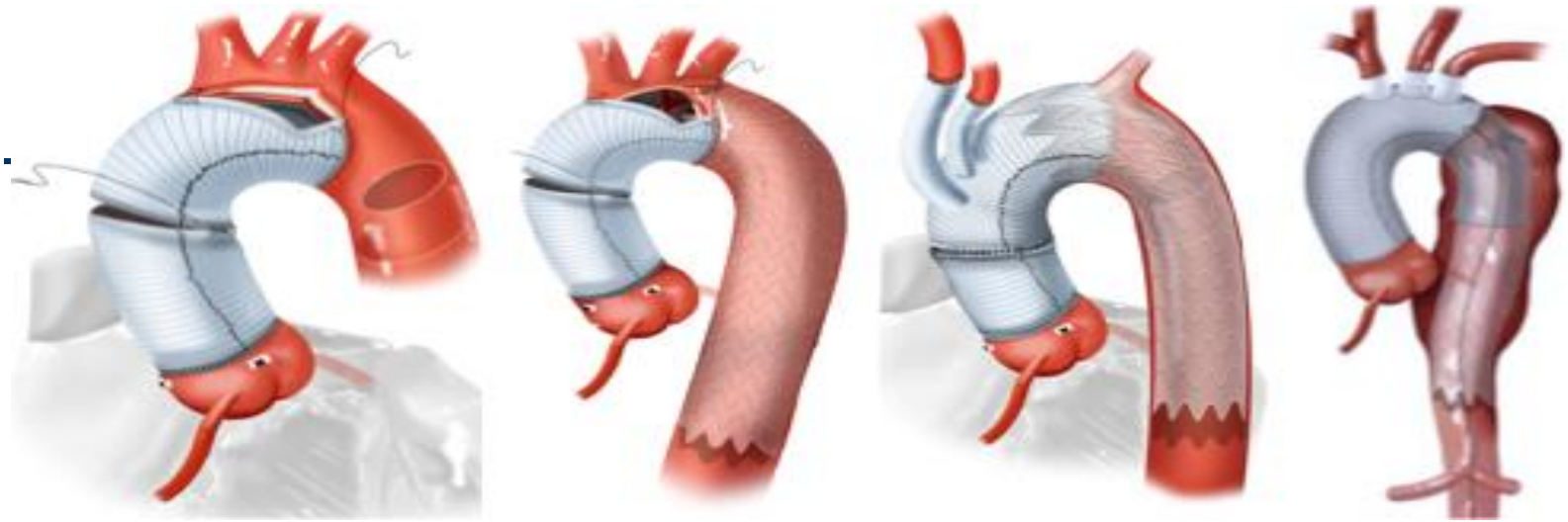

Nimesh D. Desai M.D. Ph.D.

Associate Professor of Surgery

University of Pennsylvania Health System

Perspective: Where we were ……80s-90s

- **Rudimentary understanding of the Circulation Management complexity**

- **Classical arch algorithm ……**
  - Clamped Ascending, go into Arch IF “tear” extended pa clamp

- **Massive blood product administration**
  - A lot of Dead RV’s
- **We admitted to ICU, had 4% mortality while waiting for OR**

Result: Worldwide High Mortality and CVA

A Safe Therapeutic Operation for Type A Dissection

(circa early-mid 1990's)



- Address High Morality, massive bleeding and poor neurologic outcomes

- Femoral cannulation
- Circ arrest in all cases
- No Aortic clamping until circ arrest
- OPEN anastomosis
- Re-cannulation of Graft

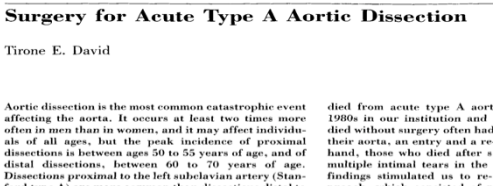

Surgery for Acute Type A Aortic Dissection

Tirone E. David

Aortic dissection is the most common catastrophic event affecting the aorta. It occurs at least two times more often in men than in women, and it may affect individuals of all ages, but the peak incidence of proximal dissections is between ages 50 to 55 years of age, and of distal dissections, between 60 to 70 years of age. Dissections proximal to the left subclavian artery (Stan-

died from acute type A aort
1980s in our institution and
died without surgery often had
their aorta, an entry and a re
hand, those who died after s
multiple intimal tears in the
findings stimulated us to re-

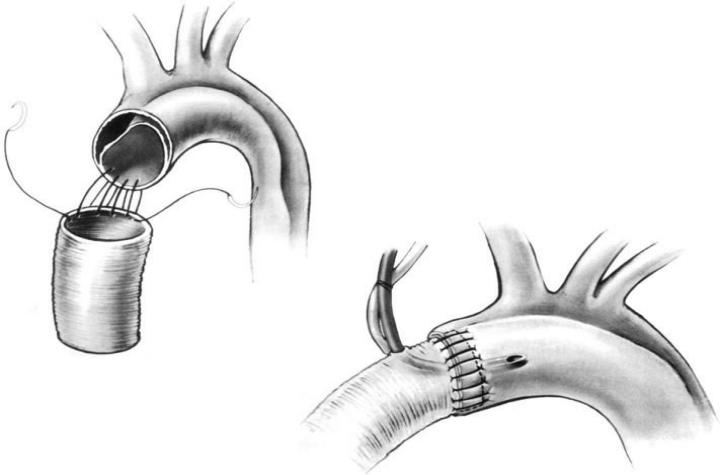

PENN Integrated Approach to Aortic Dissection

- **Rapid Admission to OR via PENNSTAR helicopter (Level I Trauma model)**

- **Routine TEE/Neuro-Cerebral Monitoring: OR as Diagnostic and Therapeutic suite**

- **Root Sparing Techniques (less complex proximal repair)**

- **Routine Open Arch repair (typically Hemiarch with HCA/RCP) using *Central Aortic cannulation***

When We Replace the Root at Penn (20% of Type A)

Connective tissue disorder (5-10%): Marfan or Loeys-Dietz syndrome

Aortic root (sinus of Valsalva segment) aneurysm (10%)

Bicuspid valve or primary leaflet abnormality
- –Not absolute indication if normally functioning BAV

NUANCE: Intimal tear extending into sinus of Valsalva, especially if coronary ostium involved

Most patients have a NORMAL root dimensions prior to Type A

Acute Changes in Aortic Diameter At time of acute dissection

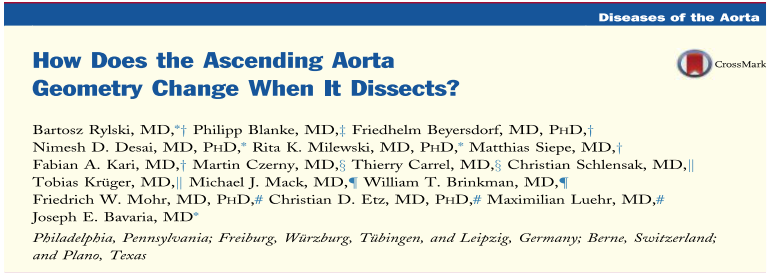
Diseases of the Aorta

How Does the Ascending Aorta Geometry Change When It Dissects?

Bartosz Rylski, MD,*† Philipp Blanke, MD,‡ Friedhelm Beyersdorf, MD, PHD,†
Nimesh D. Desai, MD, PHD,* Rita K. Milewski, MD, PHD,* Matthias Siepe, MD,†
Fabian A. Kari, MD,† Martin Czerny, MD,§ Thierry Carrel, MD,§ Christian Schlensak, MD,‖
Tobias Krüger, MD,‖ Michael J. Mack, MD,¶ William T. Brinkman, MD,¶
Friedrich W. Mohr, MD, PHD,# Christian D. Etz, MD, PHD,# Maximilian Luehr, MD,#
Joseph E. Bavaria, MD*

Philadelphia, Pennsylvania; Freiburg, Würzburg, Tübingen, and Leipzig, Germany; Berne, Switzerland; and Plano, Texas

Max Diameter Ascending:

40.1 to 52.9 cm
30% acute increase!

Root:
40.4 to 41.4 cm
Minimal change

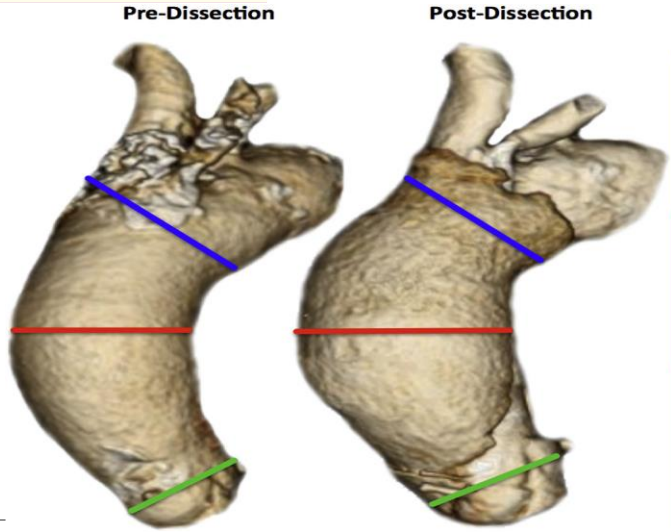

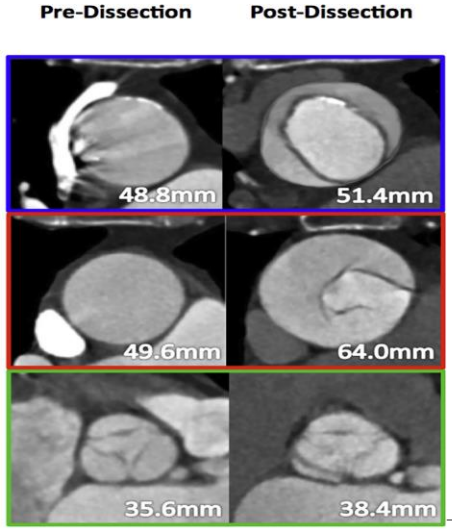

Rylski
Desai et al
JACC 2014

Aortic Valve Resuspension and Neo-Media Reconstruction

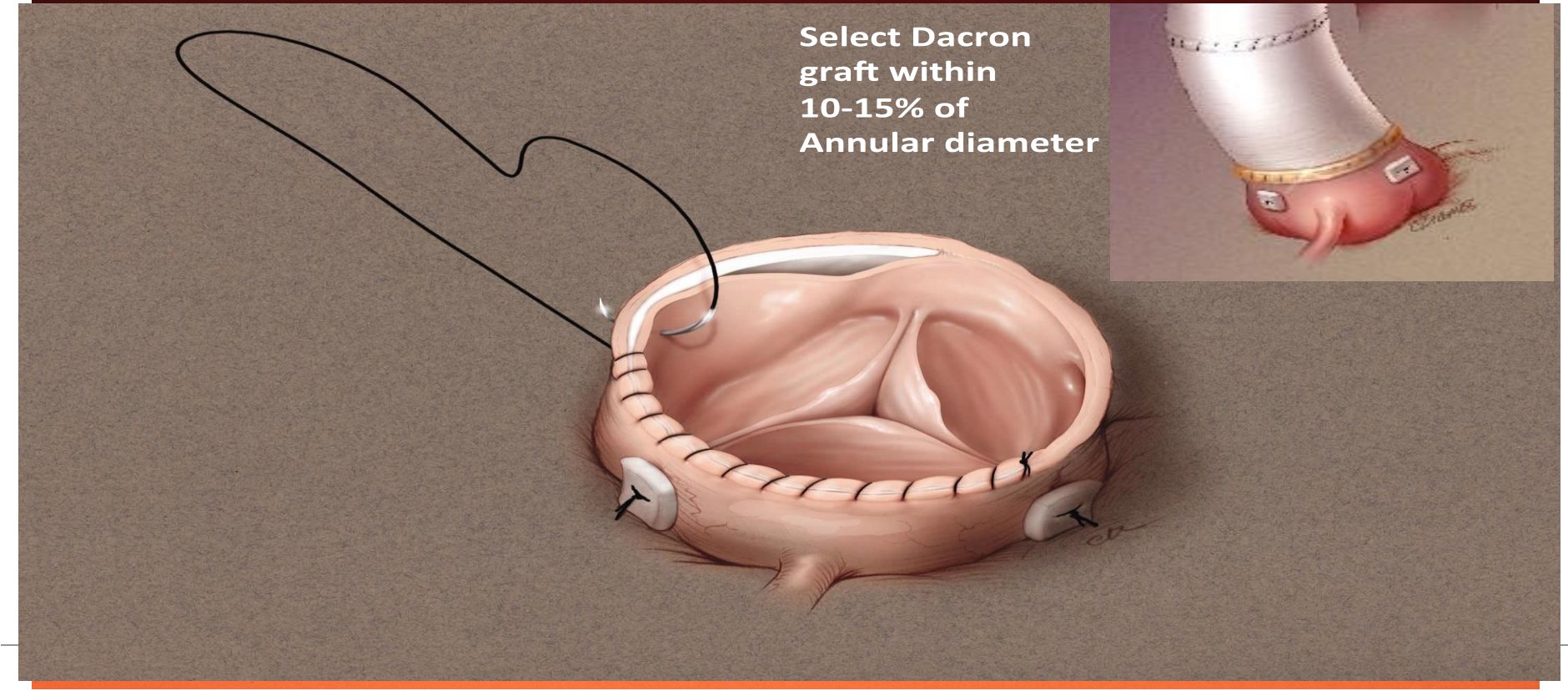

Case Presentation

58 yo M with CP/stroke symptoms

4.1 cm sinus segmet

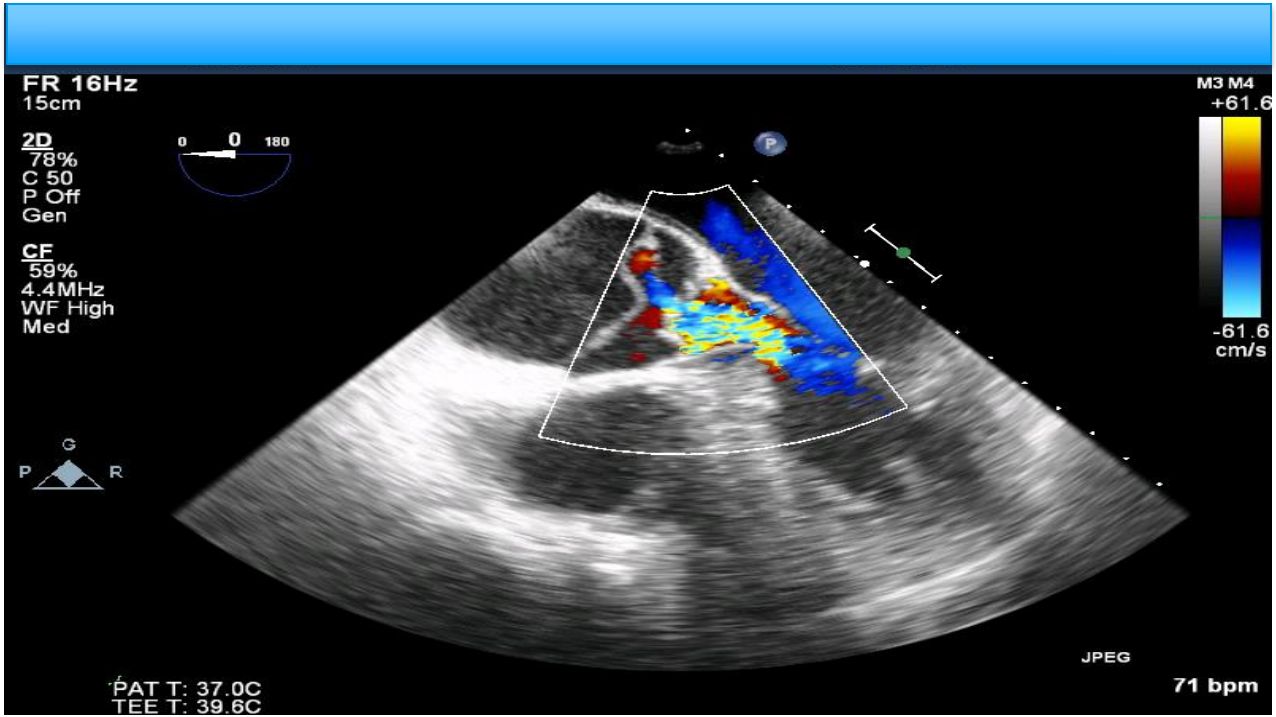

Aortic Valve Resuspension

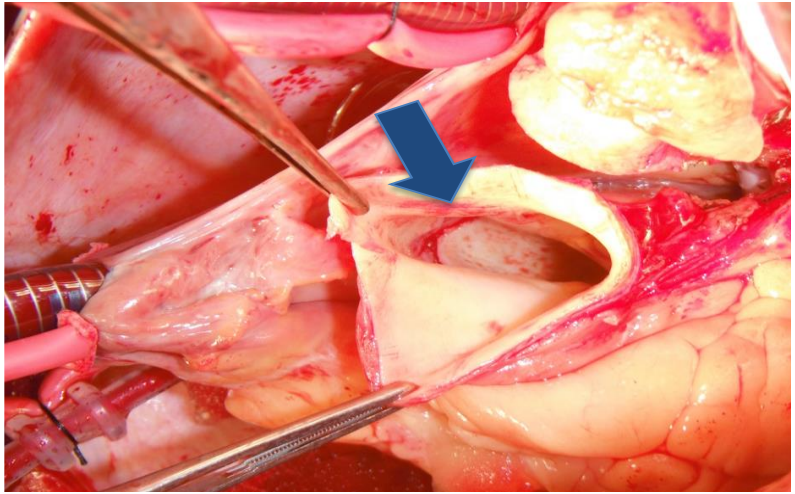

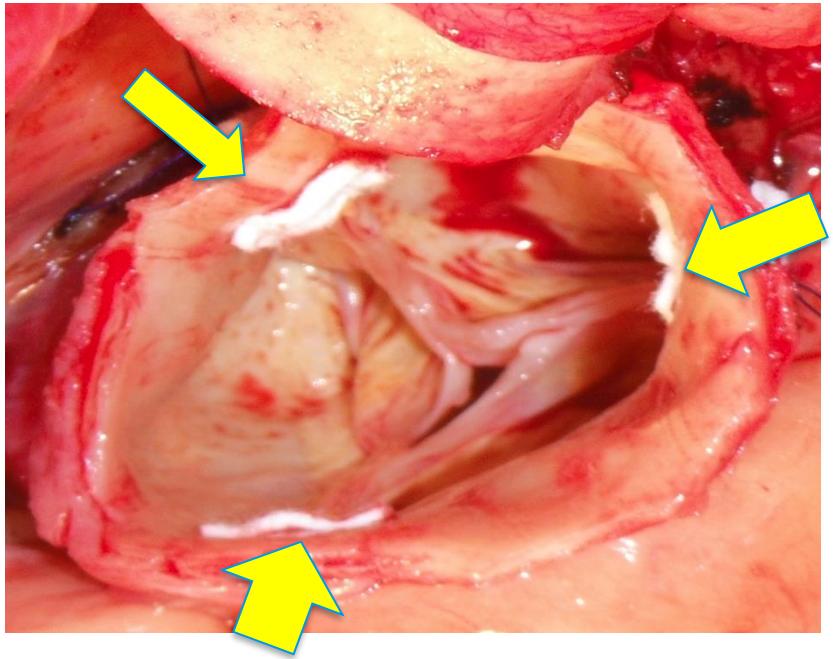

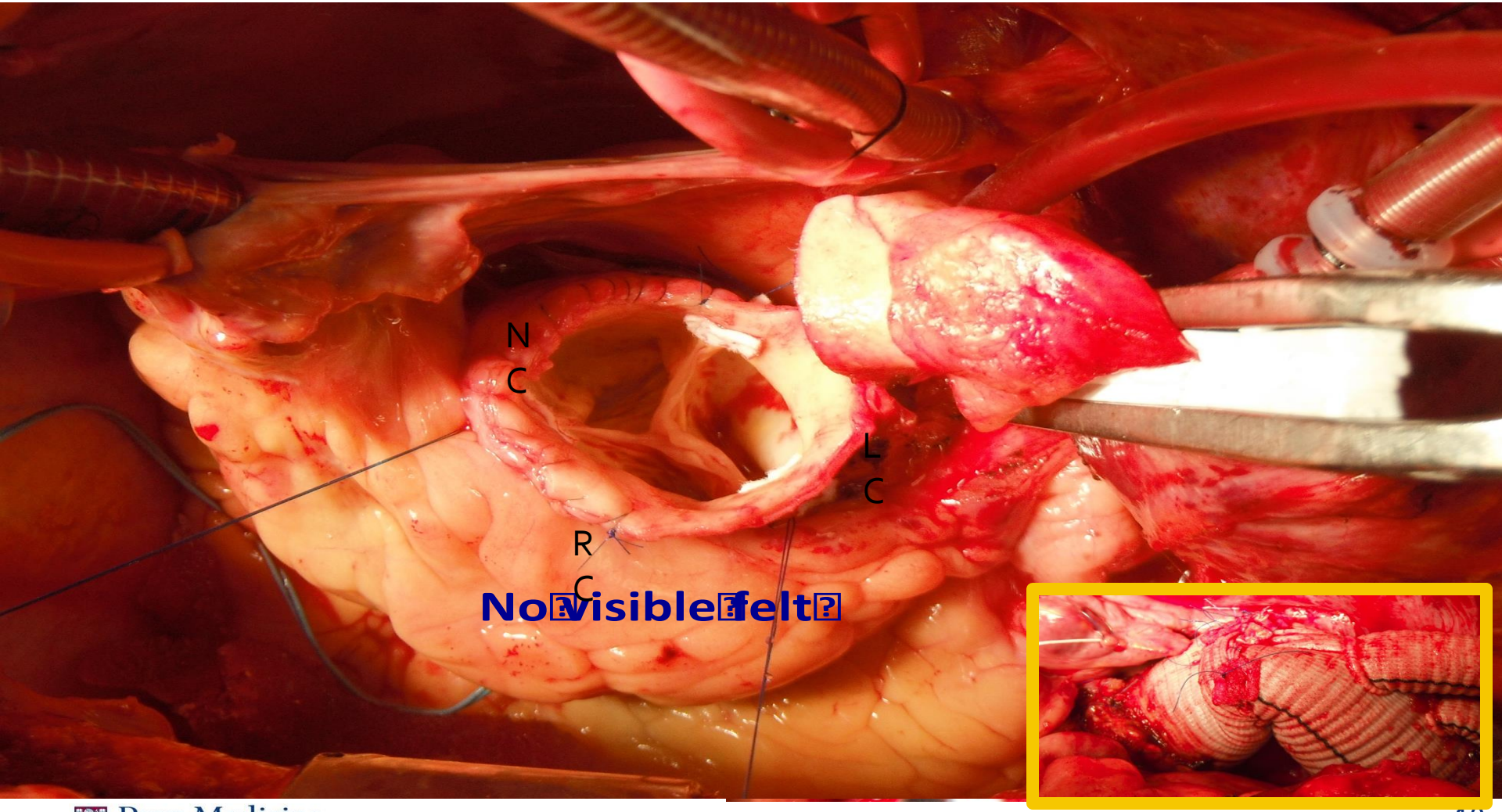
N
C
L
C
R
C
No visible/felt?

Completion Repair

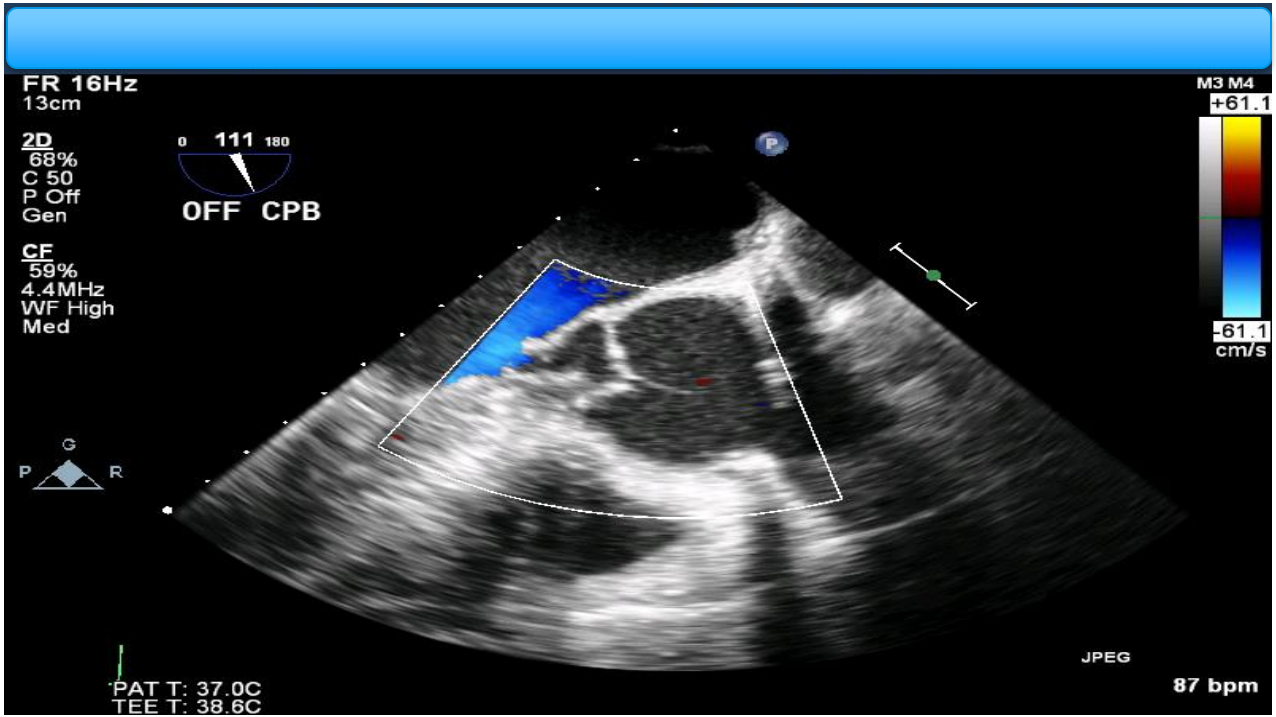

Neo-Media Root Repair Outcomes

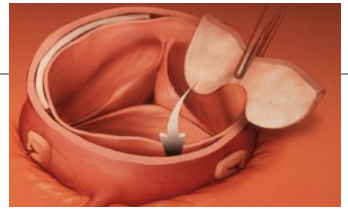

Long-Term

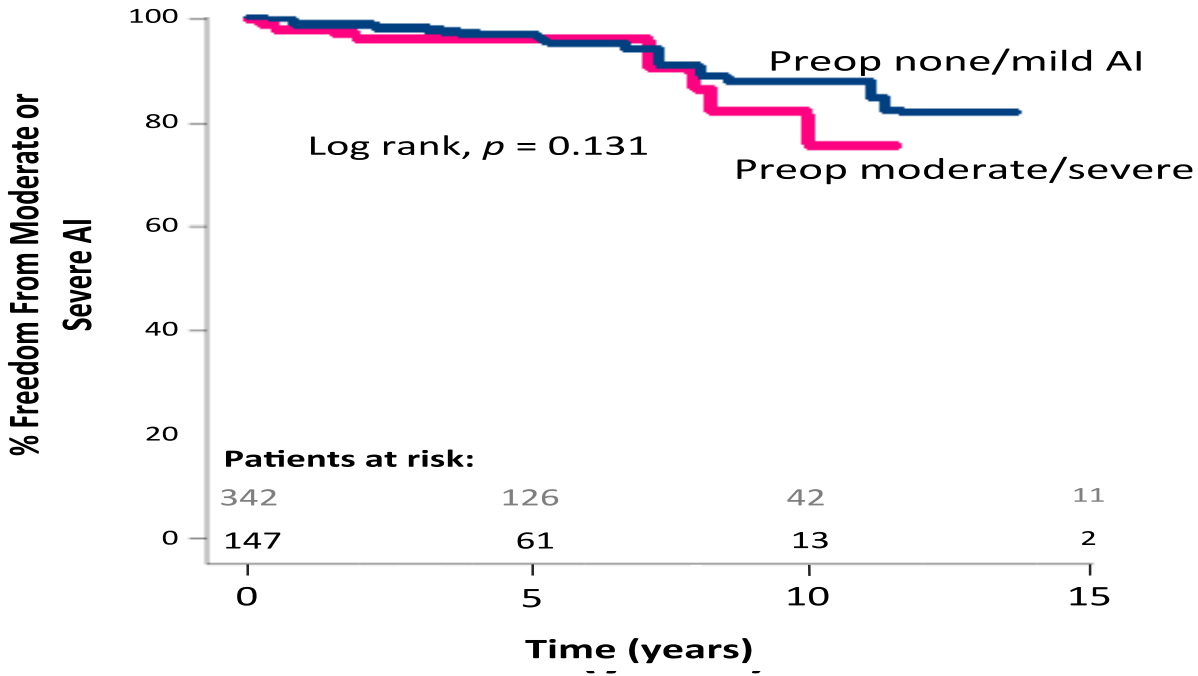

17 patients (3%) required proximal reoperation:

- 10 for AI, including 3 with concomitant pseudoaneurysm
- 2 with root aneurysm
- 6 pseudoaneurysm
- 1 for graft infection.

Rylski, Bavaria, Desai JTCVS 2014

Late Failure in Hemi-Arch: Scope of the Problem

- Optimal repair for the dissected Arch in Acute DeBakey I remains controversial

- Late aortic complications are a REAL concern
  - Bavaria, Ishihara, DeBartolomeo
    - 25-35% late reop

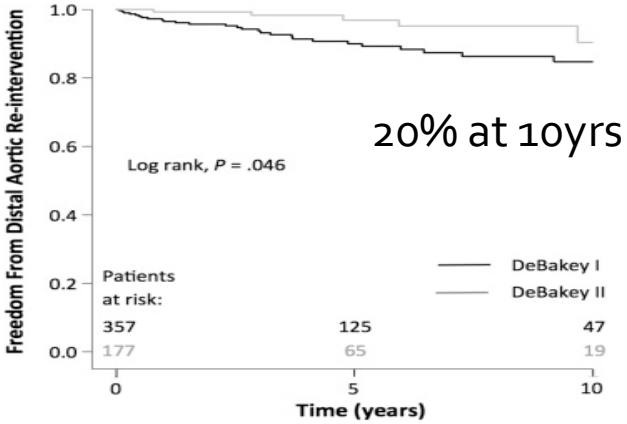

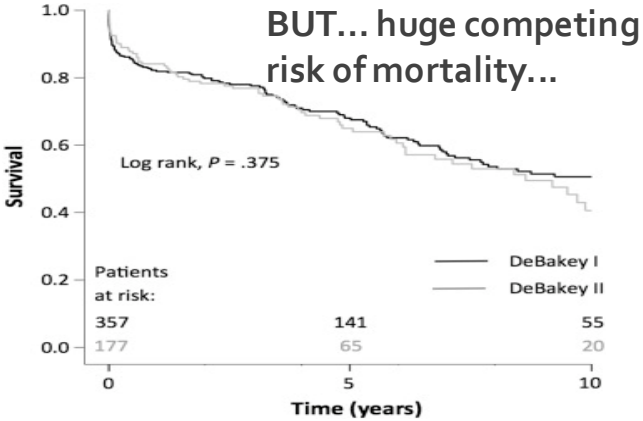

Rylski, Bavaria, Desai JTCVS

Arch Strategies in Type A Dissection

Standard Hemiarch

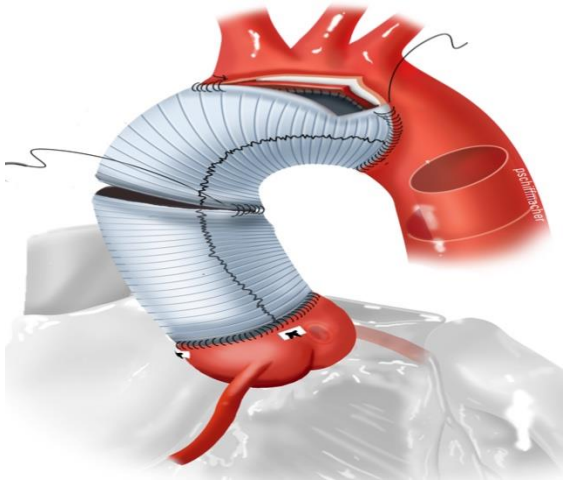

- Simple, can be done by most surgeons
- Short HCA – can use RCP
- May have poor late TEVAR options, residual malperfusion, Arch dissection

Hemiarch + Antegrade FET

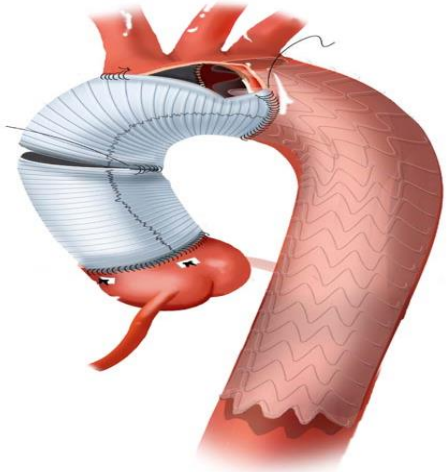

- Simple Hemiarch anastomosis
- More hemostatic, may improve malperfusion
- May have residual Arch/supra-aortic dissection
- May place stent unnecessarily (20% thrombose spontaneously)– paraplegia risk,SINE, FL placement

Arch Strategies in Type A Dissection

Zone 2 Arch with delayed Branched TEVAR

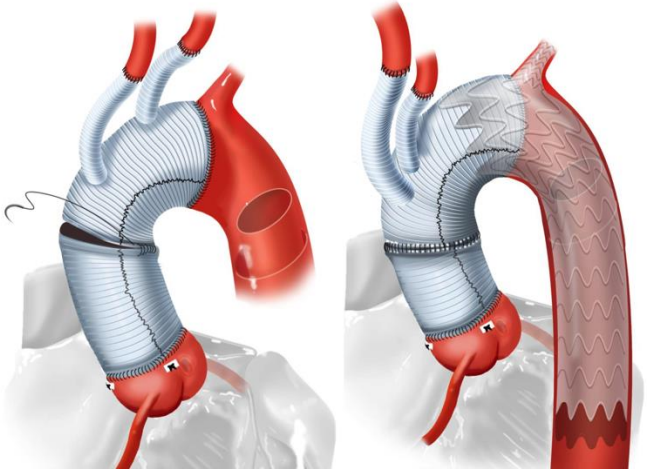

- Simpler Distal Anastomosis than Zone 3
- Can address most complex arch tears and eliminate flap in proximal head vessels
- Definitive TEVAR options
- Less risk of Recurrent larnygeal nerve injury than Zone 3, no paralysis

Total Arch +/- ET or FET

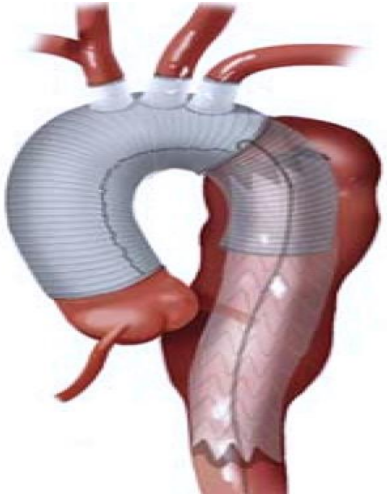

EVITA ,
Thoraflex
Registries
Mean Circ
Arrest Time
>70min

- Most complex, longest ACP time
- Can address most complex arch tears and eliminate flap in proximal head vessels
- Definitive TEVAR options, DTA open repair without circ arrest
- Higher Laryngeal nerve, Paraplegia risk

Results: Procedural Outcomes

	Hemi-arch	Hemi-arch +TEVAR	Zone 2	Zone 3	P-value
	N=430	N=70	N=40	N=22	
In-hosp. mortality(%)	**63 (15)**	**10 (14)**	**4 (10)**	**6 (27)**	**0.35**
Re-exploration for bleeding	50 (12)	9 (13)	7 (18)	3 (14)	0.65
Stroke	47 (11)	3 (4)	5 (13)	2 (9)	0.32
Paraplegia/Paraperesis	2 (0.4)	3(4)	0 (0)	1(5)	0.67
Dialysis	62 (14)	8 (11)	6 (15)	4 (18)	0.85
ICU stay (+/-days)	4 (6)	3 (4)	6 (6)	3 (14)	0.28
In-hosp stay (+/-days)	11 (11)	12 (11)	16 (14)	9 (11)	0.15

Survival - ZONE 2 ARCH Protective vs Late Death

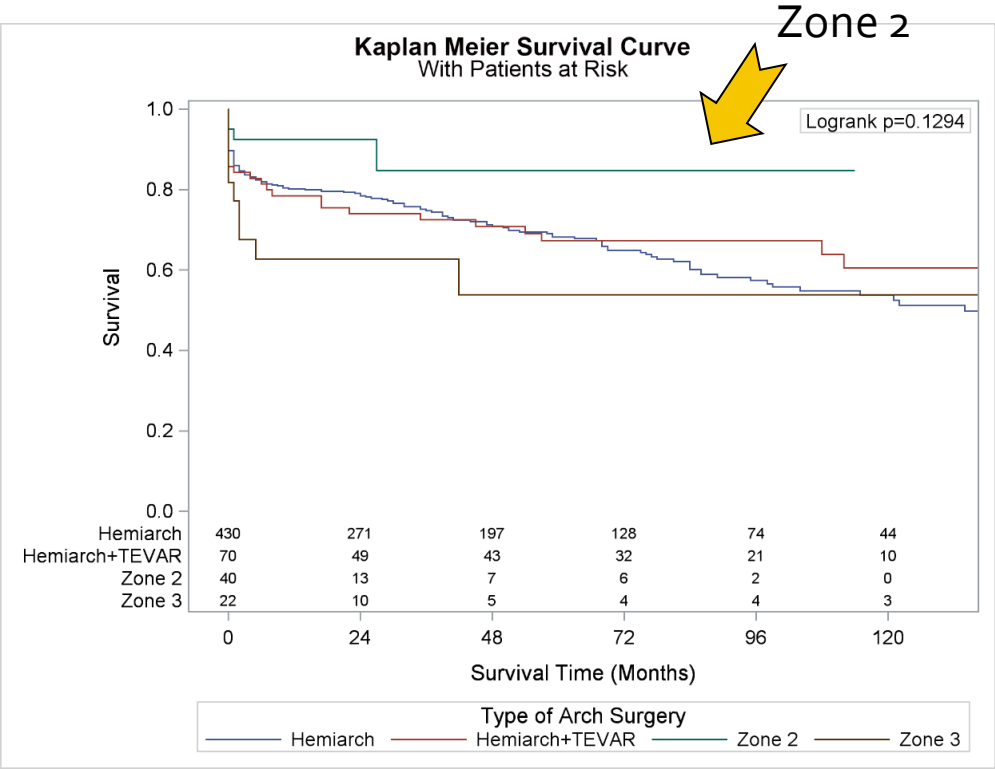

Cox Regression of Survival

Variables	Hazard Ratio	95% CI
Age >60	**2.46**	**1.8-3.3**
Hemi+TEVAR	0.91	0.5-1.4
Zone 2 Arch	**0.36**	**0.1-0.9**
Zone 3 Arch	1.69	0.8-3.5
Male	0.85	0.6-1.1
Prev.Cardiac Surg	**2.31**	**1.5-3.7**
Pre-Op AI	1.20	0.9-1.6
Penn Class BC	**2.58**	**0.9-7.1**
Penn Class B	**1.53**	**1.1-2.1**
Penn Class C	**1.94**	**0.9-4.2**

Distal Reintervention

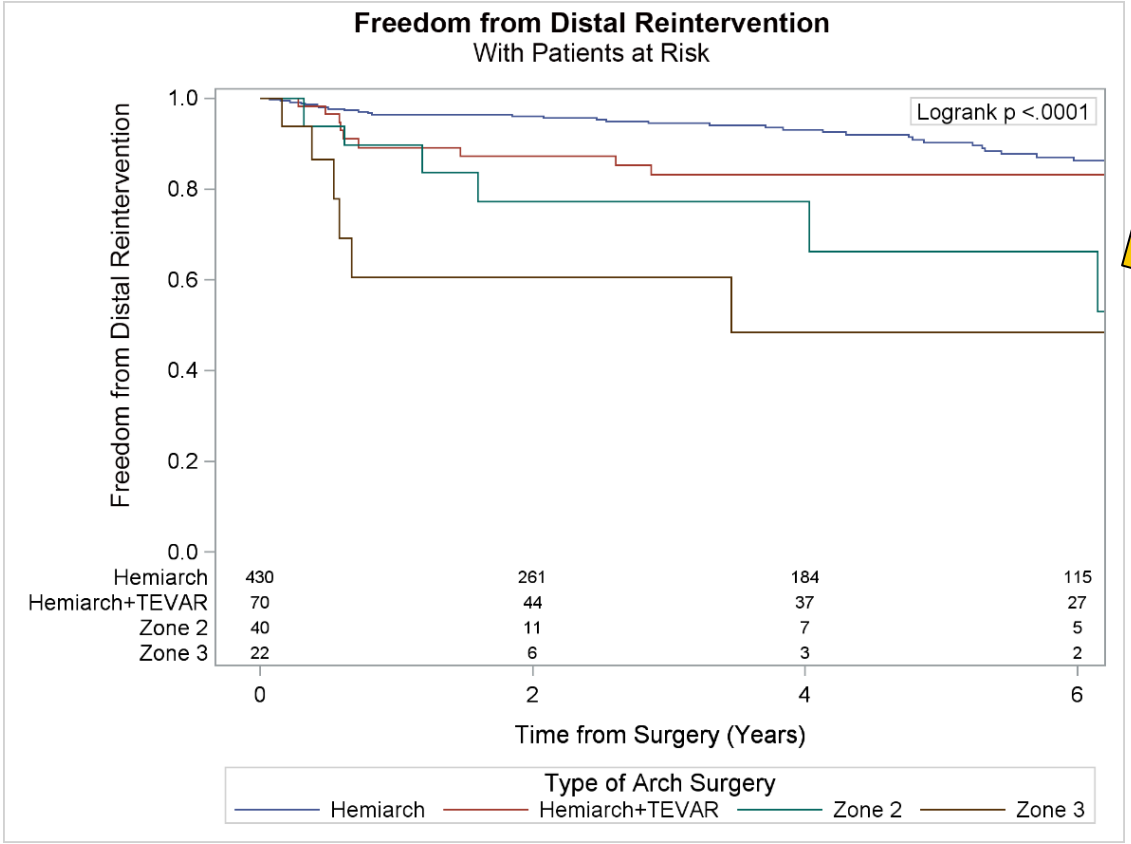

- **Distal Reintervention was more common in Zone 2 and Zone 3 Arch operations**
  - Likely related to better TEVAR options in these patients.

Open Zone 2 Repair for Acute Type

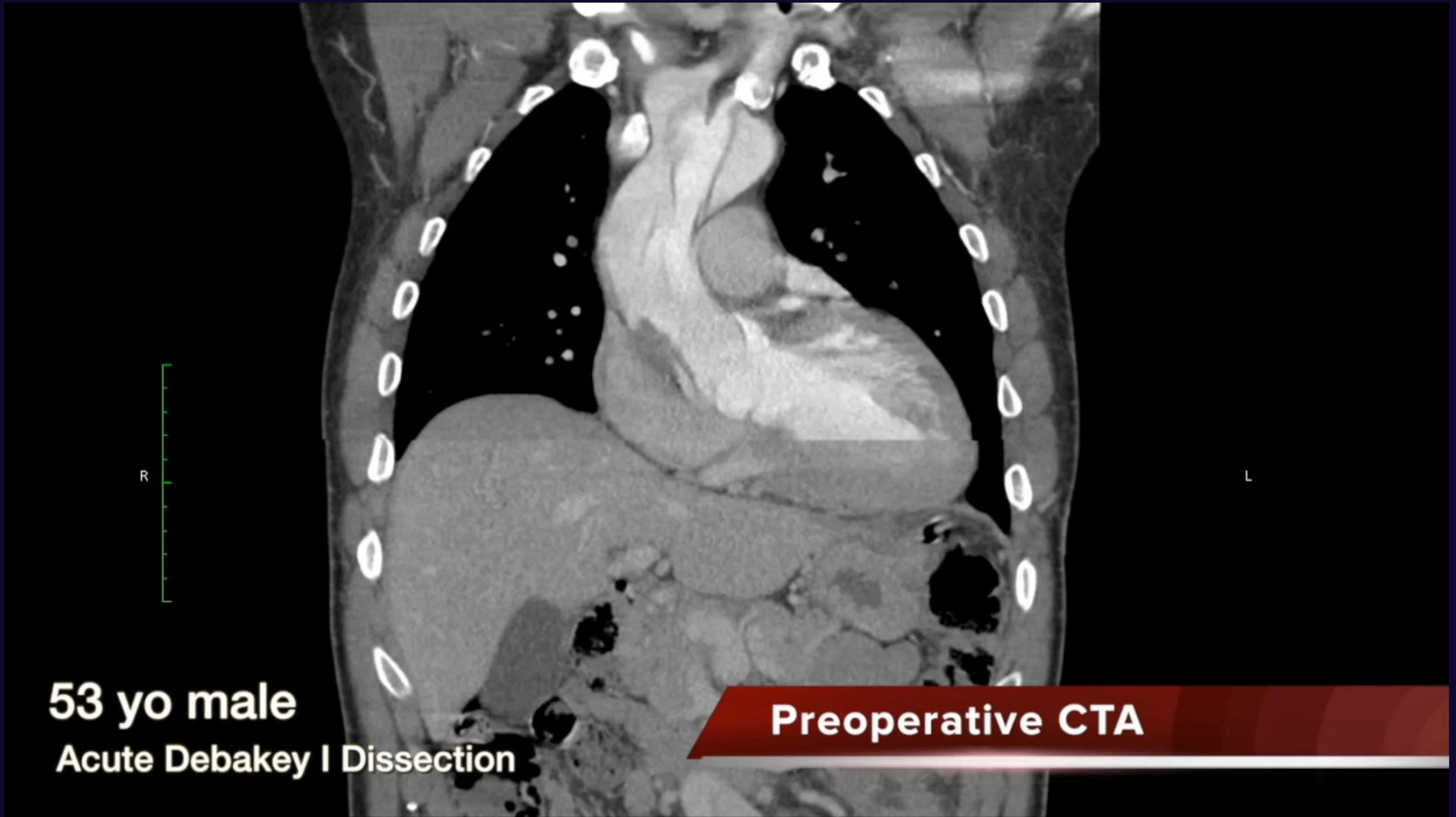

Zone 2 Arch with Single Branch TEVAR

- With the availability of Branched Grafts, we embarked on a systematic approach to performing Zone 2 Arch with later single branched TEVAR

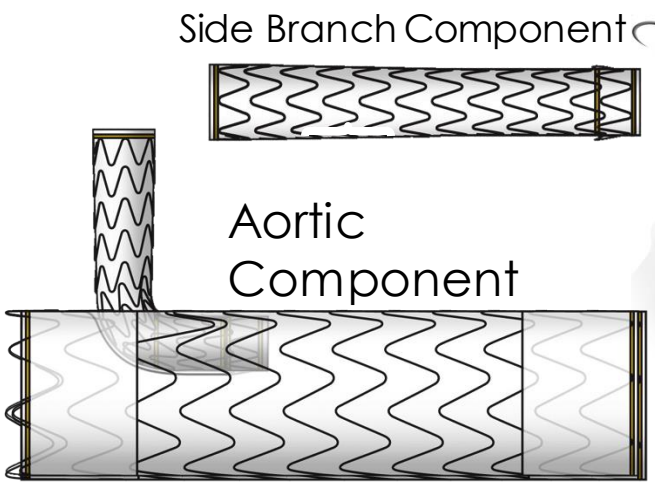

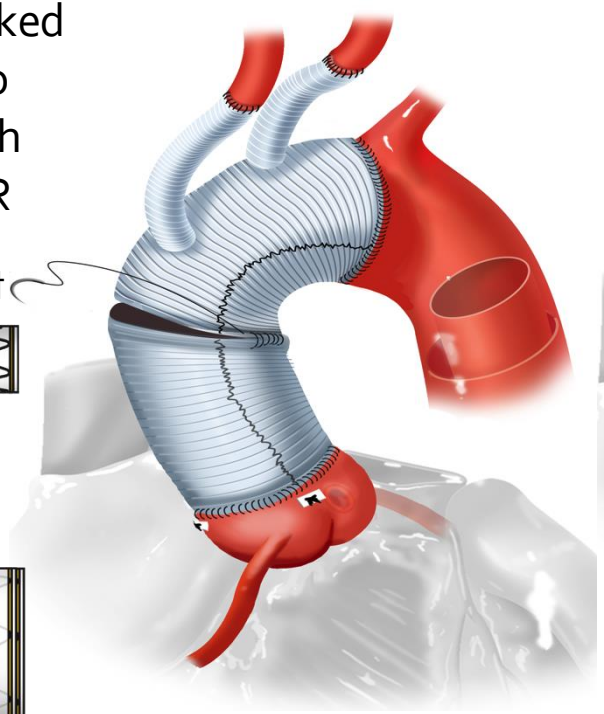

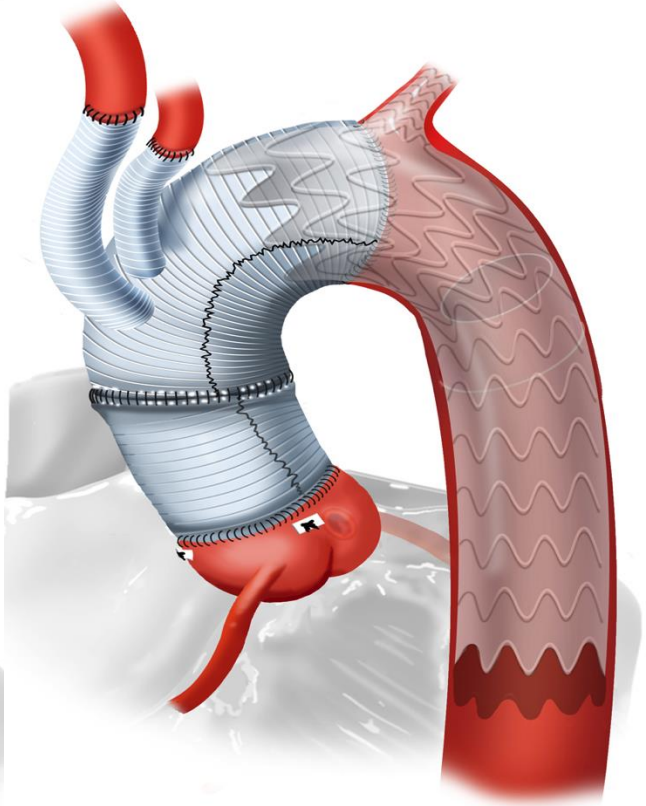

Early Results: Zone 2 Arch+Branched TEVAR

Pre-op Characteristics	N=15
Presence of either arch/DTA tear	**100% (15)**
Malperfusion	
Cerebral	**33.3% (5)**
Renal	**20% (3)**
Limb	**26.7% (4)**
Dissected Supra-Aortic Vessels	**33.3% (5)**

30 Days Post-Op	N=15
Mortality	0%
Post-Op CVA	0%
Paralysis(any)	**0%**
Rec. Laryngeal n. Injury	0%
Dialysis	**0%**
FL thrombosis at level of Stent	100%
FL Thrombosis Below Stent	**13%**

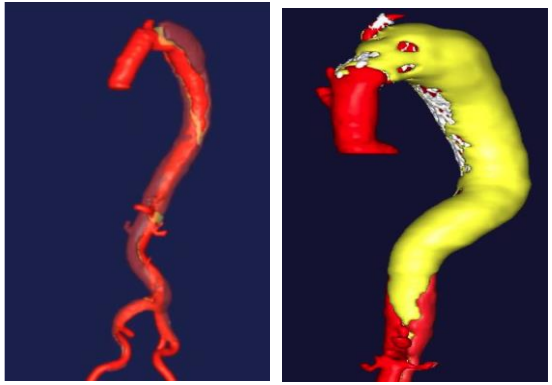

Mean ACP time 34 min

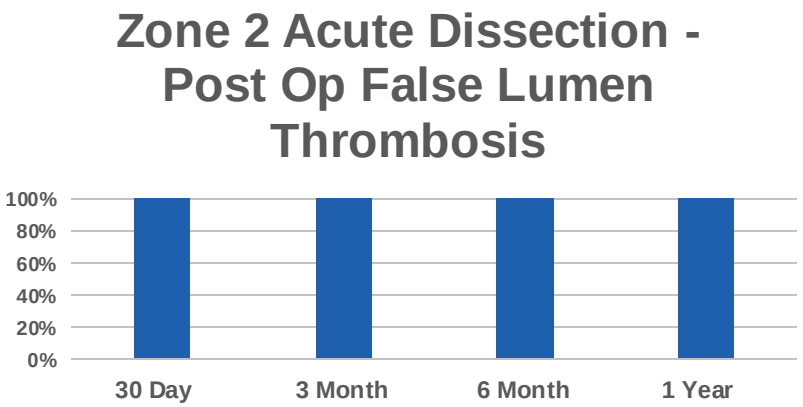

Conclusions

- Root-sparing Surgery is associated with good long-term outcomes in Acute Type A Dissection
- Among more complex arch strategies (more than hemiarch), Zone 2 Arch was associated with the shortest HCA times and superior late survival after emergent repair for DeBakey I Dissection
- Novel approaches such as single-branched TEVAR completion in a Zone 2 repair may provide a robust long-term solution for DeBakey I Dissection