September 12-14
2018
Les Comtes de Méan
Liège, Belgium

6th International Meeting on Aortic Diseases

New insights into an old problem CHU Liège, APF

www.chuliege-imaa.be

How to treat an infected aortic endograft by in-situ reconstruction with pericard tube grafts

H.-H. Eckstein

MUNICH AORTIC CENTER
Technische Universität München

Department for Vascular and Endovascular Surgery
Klinikum rechts der Isar (MRI), Munich, Germany

CHU de Liège

Disclosure of Interest

Speaker name: Hans-Henning Eckstein.....

- I have the following potential conflicts of interest to report:
- Consulting
- Employment in industry
- Shareholder in a healthcare company
- Owner of a healthcare company
- Other(s)

- **x I do not have any potential conflict of interest**

Background

- 0,4% after elective EVAR for non-ruptured AAA (Kahlberg 2016, Vogel 2008, Ducasse 2004)

- Risk factors
  - EVAR for aortic pseudoaneurysms
  - Periprocedural infections (Vogel 2008)
  - Infected aorta (primary aorto-enteric fistula)

- Many different microorganisms

- Clinical presentation:
  - Aortic bleeding/Aorto-enteric fistula
  - low-grade sepsis
  - Acute severe sepsis (Hobbs 2010)

- Which kind of therapy?

Ann Vasc Surg. 2018 Aug;51:306-313. doi: 10.1016/j.avsg.2018.02.038. Epub 2018 Jun 11.

FULL-TEXT ARTICLE

Current Evidence on Management of Aortic Stent-graft Infection: A Systematic Review and Meta-Analysis.

Li HL[1], Chan YC[2], Cheng SW[3].

- 11 papers from 2007-2016
- 402 patients (77% male), 87% EVAR, 13% TEVAR
- Aortic rupture in 10%, aorto-enteric fistula in 25%
- conservative treatment in 10%
- Surgical treatment in 90% (in-situ replacement, femoral vein, antibiotic bonded grafts etc.)

- 30-day mortality was 17%, follow-up mortality was 28%
- Survival rates
  - Infected EVAR: 58% vs. infected TEVAR 27%
  - Surgical treatment 58% vs. conservative treatment 33%
  - Without AE fistula 72% vs. 33% in the presence of an AE-fistula

16 patients with infected (T)EVAR (2008-2018)

- Infected EVAR 11 pts, infected TEVAR 5 pts
- Male gender in 75%, median age: 67 yrs (55-76)

- Initial indications for EVAR (11 pts):
  - Non-ruptured AAA (elective): 9
  - Aorto-enteric fistula: 1
  - Infected convential aortic graft (bridging) 1

- Initial indications for TEVAR (5 pts):
  - Non-ruptured TAA (elective) 2
  - Aortic transsection 1
  - Ruptured type B dissection 1
  - Ruptured TAA 1

Clinical presentation

- Infected TEVAR (5 pts)
  - Aorto-esophageal fistula 3
  - Sepsis and positive PET CT imaging 2

- Infected EVAR (11 pts)
  - Mild sepsis and and positive PET CT imaging 2
  - Sepsis and positive PET CT imaging 4
  - Septic aortitis above the stentgraft 2
  - Bleeding/contained rupture 2
  - aorto-intestinal fistula 1

Therapy

- Infected TEVAR (5 pts)
  - Thoracic drainage — 1 (died)
  - Esophageal resection — 1 (died)
  - Pericard tube — 3 (2/3 died)

- Infected EVAR (11 pts)
  - Conservative with AB — 1 (still alive after 2 yrs)
  - Drainage of the AAA sac + AB — 1 (T-Branch EVAR, alive, 3 mo)

Early mortality rate of infected TEVAR — 4/5 (80%)

Early mortality rate of infected EVAR — 4/11 (37%)

Case No.1: 55 yrs, male

- 7/2007 elective EVAR for infrarenal AAA
- 10/2007 fever, sepsis
- Jan 3/2008 CTA: AAA 6,8cm, air bubbles in the AAA sack

3.1.2008

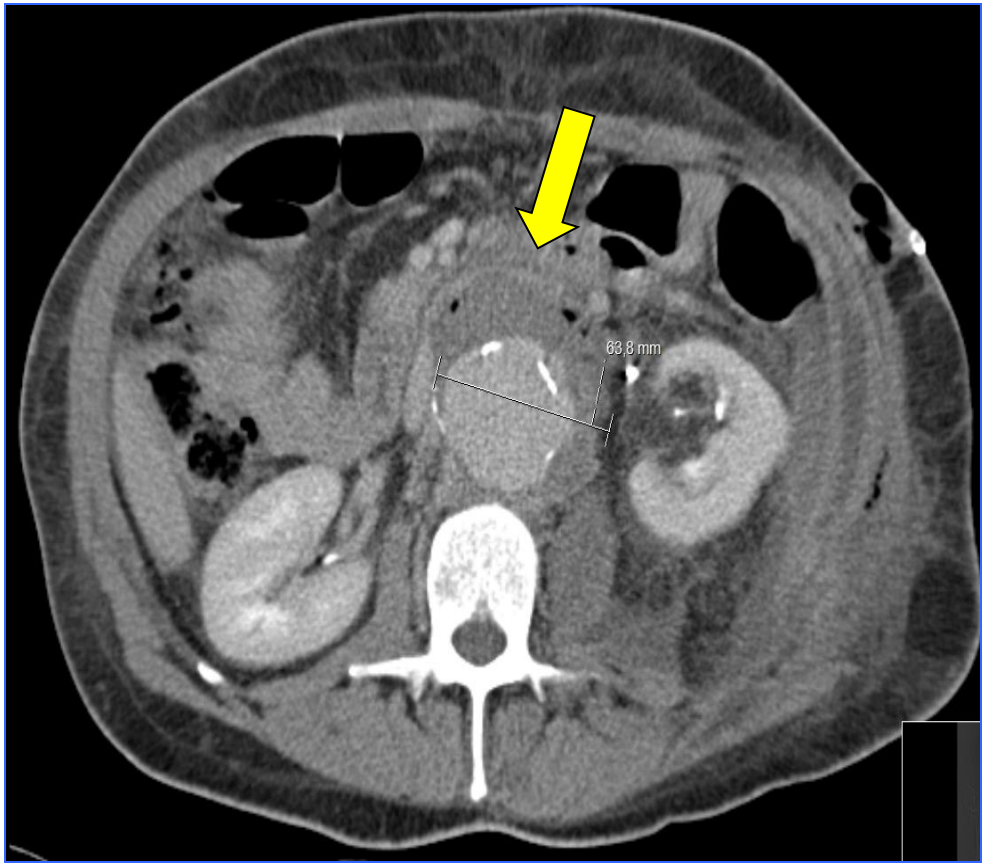

Case No.1: 55 yrs, male

- Jan 4, 2008: EVAR resection and bifurcated silver graft
- Microorganism: Staphylococcus aureus
- Jan 11, 2008 continuing sepsis, graft explanantion and aortic replacement with femoral veins
- July 2014 Patient fine, CTA ok

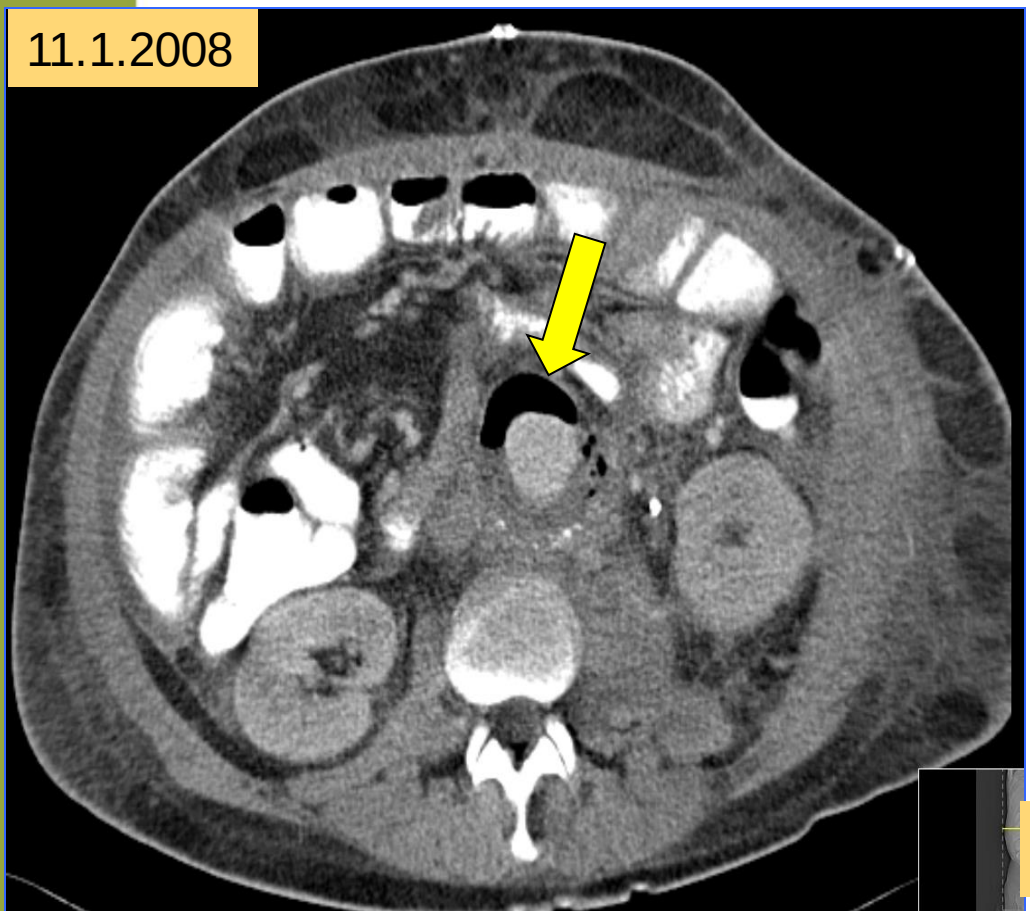

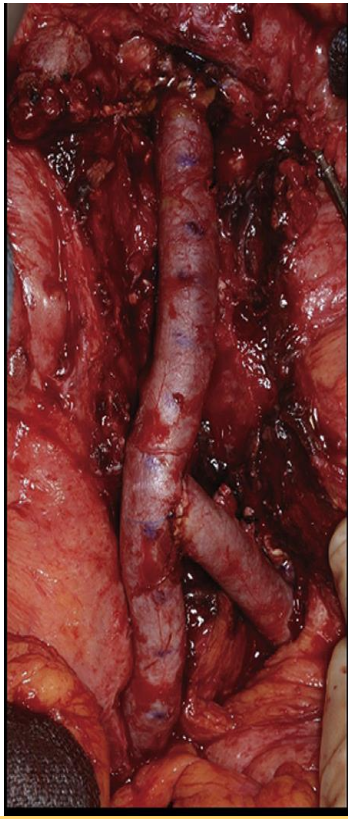

Fatima et al, JVS 2013

Characteristics of a perfect graft for in-situ replacement

- no alloplastic material
- high resistance to reinfection + degradation
- no inherent morbidity
- caliber + length customizable
- easy to handle, suturing easy!
- always available + cheap

derivate from Martha: bovine pericard

Clinical Research

Bovine Pericardium as New Technical Option for In Situ Reconstruction of Aortic Graft Infection

Brigitta Lutz,[1,2] Christian Reeps,[1,2] Gabor Biro,[2] Christoph Knappich,[2] Alexander Zimmermann,[2] and Hans-Henning Eckstein,[2] Germany

2016

Background: Alloplastic aortic graft infection is a devastating complication following aortic surgery. It is associated with excessively high mortality and morbidity caused by anastomotic rupture or septicemia. Many authors consider in situ replacement after complete surgical graft removal as the method of choice. However, there is an ongoing debate about the most suitable material for reconstruction. We present our first experiences with replacing the descending and infrarenal aorta using custom-made bovine pericardium grafts.

Material and methods: From January 2013 to 2015, 13 patients (10 male, median age 70 years, range 53–84) were treated for 5 early-graft infections after open reconstructions and 7 late graft infections (1 TEVAR, 2 EVAR, and 4 open reconstructions), and 1 patient was treated for mycotic aneurysm. Septicemia was evident in 8 patients, whereas 5 patients were presented with low-grade infection. In all cases, graft infection was proven by a synopsis of clinical findings, laboratory tests, imaging, and microbiologic tests (positive pathogen detection in 11 patients). Cutaneous and aortoenteric fistulae were present in 3 and 4 patients, respectively. All patients received an in situ replacement using a hand-sewn xenoprosthesis or patch made from a bovine pericardium sheet. Follow-up was routinely performed 3, 12, and 24 months after discharge.

Results: For reconstruction, 4 pericardium tubes, 7 bifurcated grafts, and 2 large patches were implanted in situ. Technical success was 100%. Median length of hospital stay was 44 days (range, 20–136 days), with an in-hospital mortality rate of 7.7% ($n = 1$). Major procedure- and disease-related complications were temporary ($n = 2$) and permanent dialysis ($n = 1$), limb loss ($n = 1$), and long-term ventilation ($n = 5$). Complete infection control and initial healing could be achieved in 75% ($n = 10$). During the follow-up (median 9 months, range: 1–27 months), primary graft patency was 100%, and mortality was 41.7%. We observed 2 secondary ruptures due to reinfection at 4 and 7 months.

Conclusions: Custom-made bovine pericardium grafts provide a good option for in situ replacement following early or late aortic graft infection. Despite of its high biocompatibility, pericardium provides not an absolute protection against ongoing retroperitoneal infection. For the treatment, the principles of septic surgery need to be applied and close follow-up is mandatory.

Surgical technique

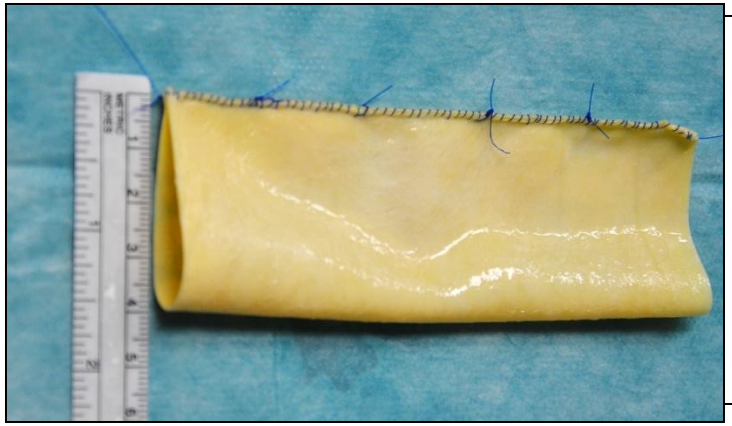

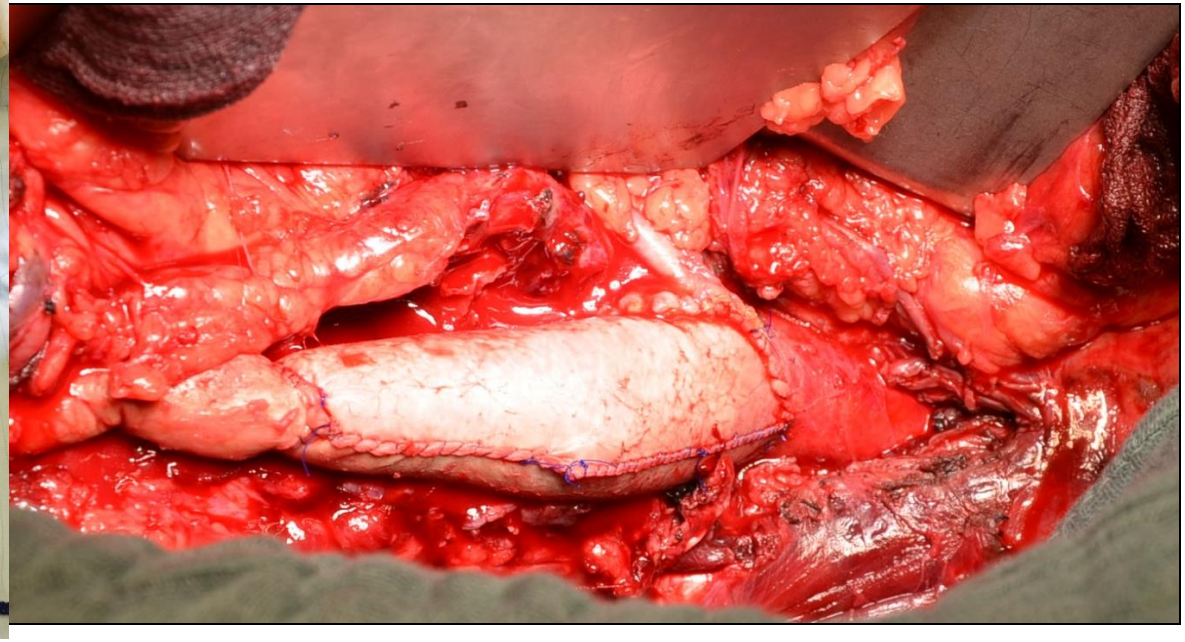

Surgical technique



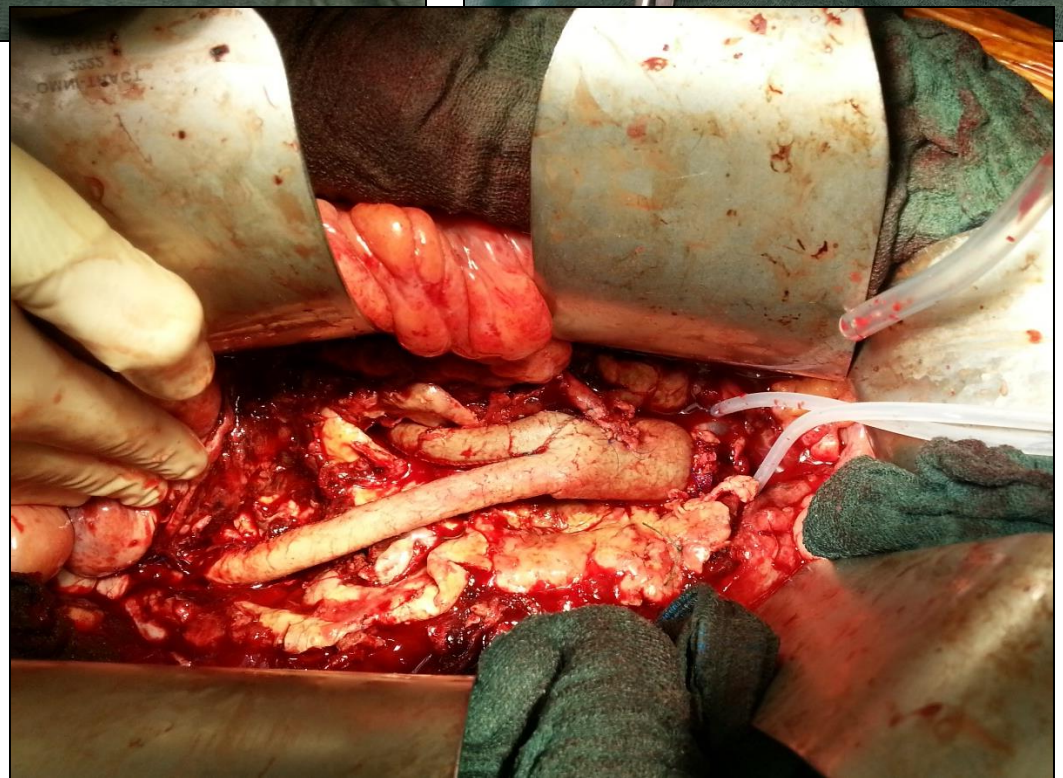

Case No. 2: 72 yrs, male

- 2009 EVAR for infrarenal AAA
- Dec 2012 retroperitoneal abscess left-sided
- Jan 22, 2013 EVAR explantation and pericard tubing
- Microrganism: Salmonella

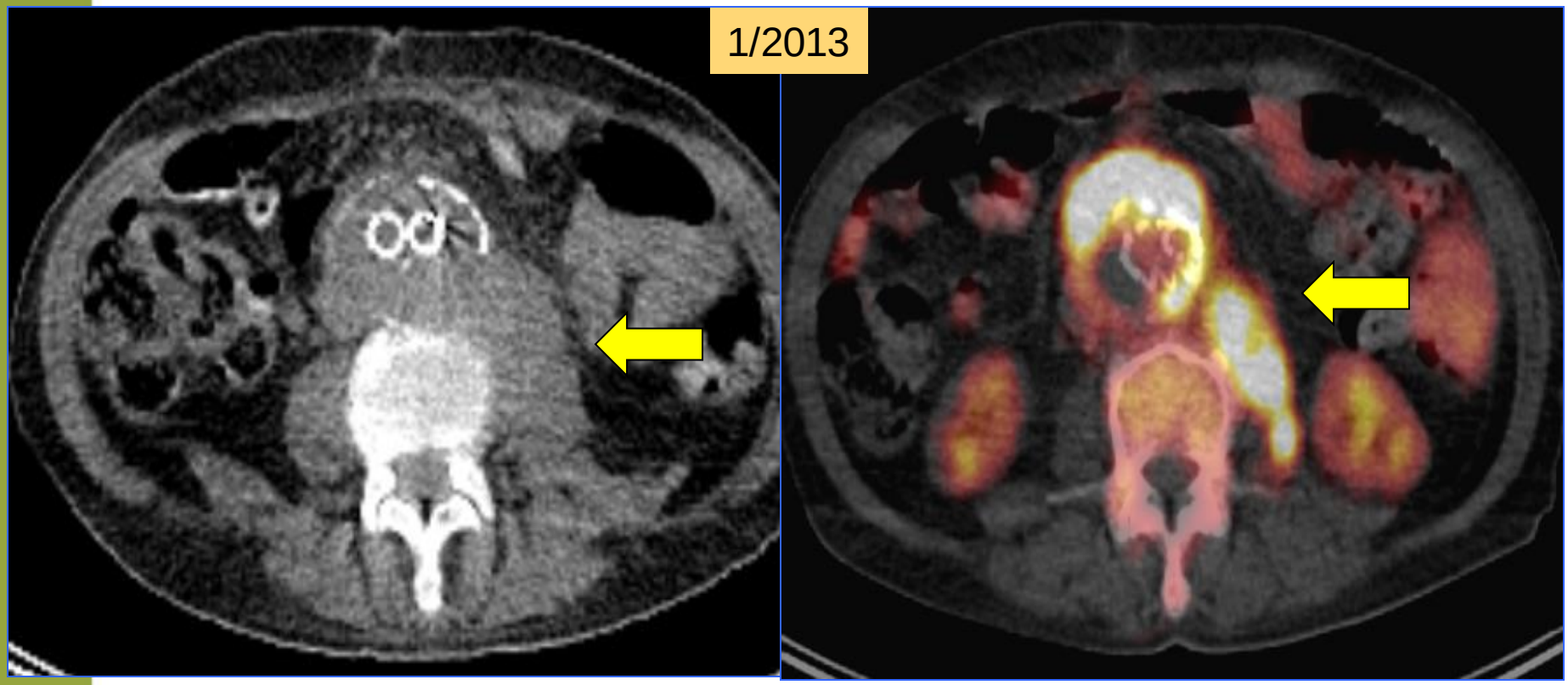

Case No. 2: 72 yrs, male

June 2016: Patient fine, CTA ok

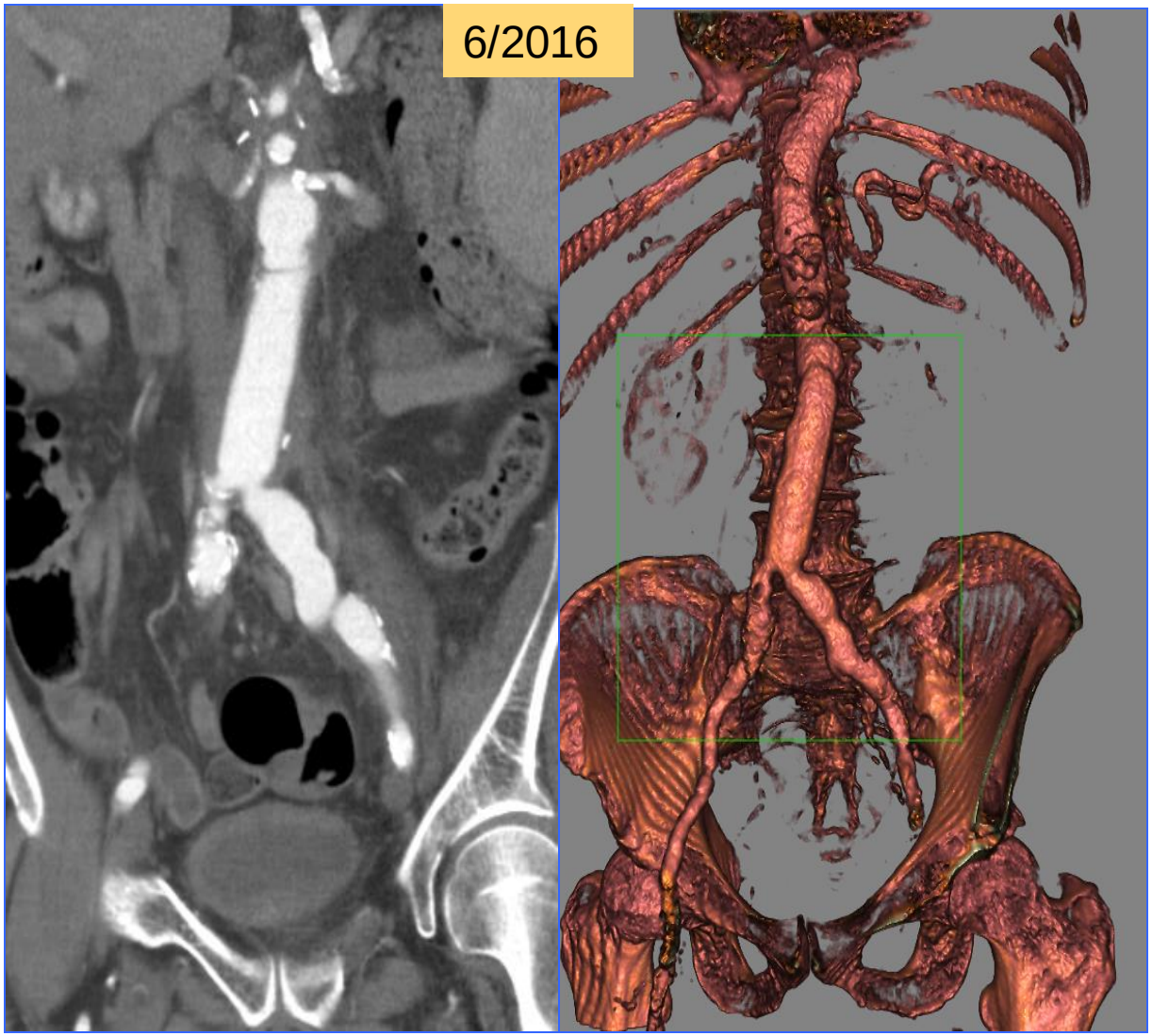

Infected (T)EVAR: our treatment algorithm

- ✓ Diagnostics: CTA, PET-CT, Gastroscopy, blood samples
- ✓ **Conservative therapy** (+/- drainage of the AAA sac) may be considered, if the infection is mild and the patient is stable
- ✓ Explantation of infected grafts and replacement of the aorta with **bovine pericard tubes or bifurcations**
- ✓ Aorto-enteric fistula: duodenal/esophageal resection
- ✓ Omemtum coverage if technically feasible
- ✓ Liberal indication for second look thoracotomy/laparotomy
- ✓ Antibiotics for at least three months
- ✓ CTA/PET-CT after three and 12 months

Conclusions

- (T)EVAR infection is a life-threatening condition
- most pts need (T)EVAR explantation
- Pericardial tubing/bifurcation currently our first choice
- Long-term data are still missing

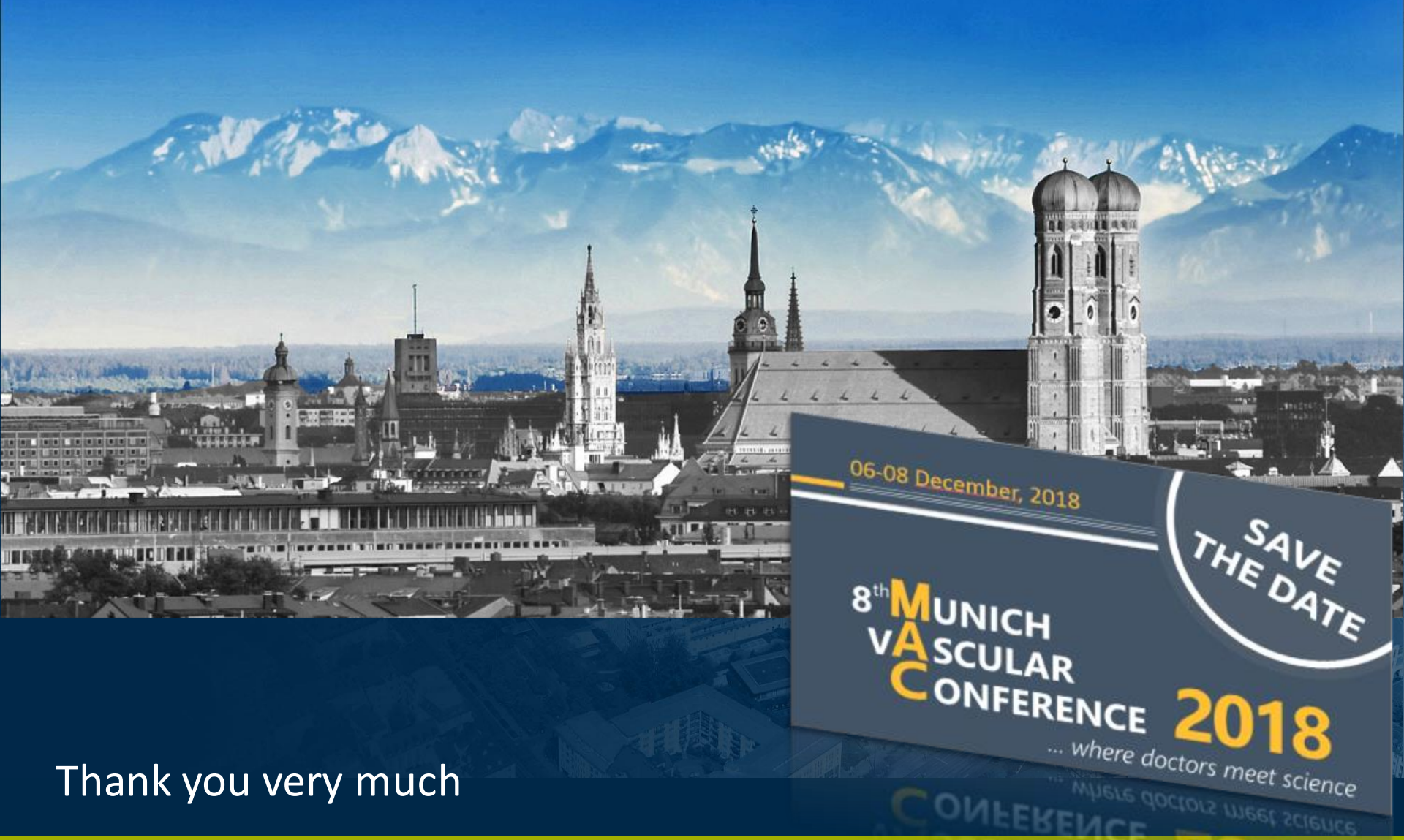

Thank you very much

H.-H. Eckstein

Department for Vascular and Endovascular Surgery
Klinikum rechts der Isar (MRI), Munich, Germany

MUNICH AORTIC CENTER
Technische Universität München

Bovine pericardium for other indications

freedom from re-infection and revision

100% (141 pts) and **90%** after **1 and 5y** after bovine pericardium valve replacement of **prosthetic valve infection in endocarditis** *K. Meszaros et al. Ann Thoracic Surg 2011*

98% (50/51) after **2.4y** **femoral arterial reconstruction** with bovine pericardium after alloplastic graft infection *W. MacMillan et al. JVS 2011*

75% (11/15) after **2.0y** (5-83mo): self made bovine pericardium tube grafts for aortic reconstruction in **thoracic aortic graft infection** *M. Czerny et al. Ann Thoracic Surg 2012*

Diagnosis of Aortic Graft Infection: A Case Definition by the Management of Aortic Graft Infection Collaboration (MAGIC)

EJVES 2016

O.T.A. Lyons [a,b], M. Baguneid [c,d], T.D. Barwick [e,f], R.E. Bell [a], N. Foster [g], S. Homer-Vanniasinkam [h,i], S. Hopkins [j], A. Hussain [k,l], K. Katsanos [m,n], B. Modarai [a,b], J.A.T. Sandoe [g,o], S. Thomas [p], N.M. Price [q,*]

	CLINICAL / SURGICAL	RADIOLOGY	LABORATORY
MAJOR CRITERIA	• Pus (confirmed by microscopy) around graft or in aneurysm sac at surgery • Open wound with exposed graft or communicating sinus pseudoaneurysm	• Peri-graft fluid on CT scan ≥ 3 months after insertion	• Organisms recovered from an explanted graft
MINOR CRITERIA	• Localized clinical features of AGI e.g. erythema, warmth, swelling, purulent discharge, pain • Fever ≥38°C with AGI as most likely cause	• Other e.g. suspicious peri-graft gas/fluid/soft tissue inflammation; aneurysm expansion; pseudoaneurysm formation; focal bowel wall thickening; discitis/ osteomyelitis; suspicious metabolic activity on FDG PET/ CT; radiolabelled leukocyte uptake	• Blood culture(s) positive and no apparent source except AGI • Abnormally elevated inflammatory markers with AGI as most likely cause e.g. ESR, CRP, white cell count

Aortic graft infection should be **suspected,** if one major criterion or two minor criteria from different categories are present

Aortic graft infection is **diagnosed** if there is one major criterion plus any criterion from another category